

# Efficacy of Fenestration Technique for Lumbar Disc Excision in Pain Relief

JAWAD JAN ARIF<sup>1</sup>, SUBHAN SHAHID<sup>2</sup>, TANVEER AFZAL<sup>3</sup>, MUHAMMAD ABUBAKAR<sup>4</sup>, ALI IRFAN<sup>5</sup>

<sup>1</sup>Consultant Neurosurgeon in a Private Hospital, (Kazi Hospital Temple Road Lahore)

<sup>2</sup>Assistant Professor Orthopedics Sir Ganga Ram Hospital Lahore

<sup>3</sup>Associate Professor Orthopedics, Sir Ganga Ram Hospital Lahore

<sup>4,5</sup>Senior Registrar at Sir Ganga Ram Hospital Lahore

Correspondence to: Jawad Jan Arif, Email: [Jawadjan72@hotmail.com](mailto:Jawadjan72@hotmail.com)

## ABSTRACT

**Objective:** To determine the outcomes of lumbar disc excision by fenestration technique for pain relief in lumbar radiculopathy due to prolapsed intervertebral disc.

**Methodology:** This is a descriptive study conducted in a joint venture of orthopedic and neurosurgeons in a private hospital of Lahore. Study was completed in six months duration from July to December 2022. All patients presenting with lower back pain, straight leg raise test positive on <60 degrees and prolapsed disc at the level of L4/L5 or L5/S1 L discs on MRI. Those with multilevel disc prolapse, previous history of spinal surgery, cauda equine syndrome and patients with lumbar stenosis were excluded from the study. All study patients were operated under general anesthesia in knee chest position. Efficacy of the procedure was determined using Dennis Pain Scale. Important findings were documented when patient was discharged. SPSS version 20 was used for statistical analysis.

**Results:** 125 patients were studied including 73(58.4%) males and 52(41.6%) females. Patients with the age of 20-60 years were included in this study with the mean age of  $47.3 \pm 5.2$  years. Most commonly involved disc level was L4-L5 in 77(61.6%) and L5-S1 in 48(38.4%) cases. Unilateral radicular pain was present in 94(75.2%) cases and bilateral pain was present in 31(24.8%) cases. According to Dennis Pain Scale out of 125 cases 78(62.4%) patients presented in Dennis pain scale P4 and among them complete recovery achieved in 70(89.7%) cases.

**Conclusion:** Surgical intervention is necessary in selected patients with prolapsed intervertebral disc with chronic unilateral or bilateral radicular pain. Fenestration technique for disc excision is a very good procedure for prolapsed disc.

**Keywords:** Sciatica, Disc Excision, Prolapsed Disc, Radiculopathy

## INTRODUCTION

Low back pain is a very common problem among 80-85% adolescents and adults in our community. It causes disability in patients limiting their activity and influence their routine activities. Sciatica occurs in >40% cases with lower back pain. Significant sciatica pain is found in 4-7% cases. Lower back pain is a second most common medical problem causing absence from the job. This pain occurs due to prolapsed intervertebral disc irritating dura mater around nerve roots hence. Hence this pressure on nerve roots causes radicular pain, numbness in respective dermatomes, abnormal reflexes and weakness in relevant myotomes. In 1934 Mixter and Barr found that sciatica is associated with herniated intervertebral disc so they operated such patients using extensive laminectomy technique. In previous literature extradural removal of herniated disc and inter laminar fenestration has been used and it proved to be much safe technique in selected patients. There is no membrane formation and spinal instability in this approach. Recently many new techniques have been introduced like percutaneous endoscopic lumbar discectomy (PELD), young endoscopic spine system (YESS) and percutaneous lumbar disc decompression (PLDD) but these procedures need high expertise and skills which are not available commonly at our setups while disc excision by fenestration technique is relatively easy and can be performed by most of the orthopedic and neurosurgeons even in small hospitals in peripheral areas. This study was conducted to find out outcomes of fenestration technique for prolapsed lumbar disc using interlaminar approach in those patients eligible for surgical intervention.

## METHODOLOGY

This is a descriptive study conducted in a joint venture of orthopedic and neurosurgeons in a private hospital of Lahore. Study was commenced in July and completed after six months duration in December 2022. Study sample was calculated using WHO sample size calculator. All patients presenting with lower back pain, straight leg raise test positive on <60 degrees and prolapsed disc at the level of L4/L5 or L5/S1 L discs on MRI. Those with multilevel disc prolapse, previous history of spinal surgery, cauda equine syndrome and patients with lumbar stenosis

were excluded from the study. All study patients were operated under general anesthesia in knee chest position and upper third of lower lamina and lower third of upper lamina was cut if required for achieving clear view. Efficacy of the procedure was determined using Dennis Pain Scale. Pain severity was measured at the time of admission and on the day of discharge using Dennis pain scale. Post-operative Improvement in pain scale after was considered as successful procedure. On first post-operative day patients were encouraged to sit up and after three weeks of physiotherapy gradual walking was started. Important findings were documented when patient was discharged. SPSS version 20 was used for statistical analysis. Informed consent was taken from the study cases and whole procedure was explained to them.

Dennis Pain Scale

P1	No pain
P2	Minimum pain, no treatment required
P3	Moderate pain, medicines required occasionally
P4	Moderate to severe pain, sometimes absent from work
P5	Severe chronic pain, taking medicines for pain

## RESULTS

There were 125 patients in this study including 73(58.4%) males and 52(41.6%) females. Patients with the age of 20-60 years were included in this study with the mean age of  $47.3 \pm 5.2$  years. Most of the cases were between 31-40 years (33.6%) and 41-50 years (40.8%). Most commonly involved disc level was L4-L5 in 77(61.6%) and L5-S1 in 48(38.4%) cases. Unilateral radicular pain was present in 94(75.2%) cases and bilateral pain was present in 31(24.8%) cases. According to Dennis Pain Scale out of 125 cases 78(62.4%) patients presented in Dennis pain scale P4 and among them complete recovery achieved in 70(89.7%) cases. 07(5.8%) presented with Dennis scale P3 and completed recovery achieved in all of them (100%). There were 43(34.4%) cases in pain scale P5 and out of them 30(69.7%) achieved full recovery.

Out of 125 study cases 79(63.2%) used to performed heavy duty while 46(36.8%) had easy duties or office jobs. Average operating time was 75.6 minutes and average hospital stay duration was  $4.2 \pm 1.5$  days.

Table-1: Dennis pain scale preoperatively versus postoperatively in study cases (n=125)

Dennis Pain Scale (Preoperative)		Dennis Pain Scale (Postoperative)	
Scale	Frequency	Scale	Frequency
P1	-	P1	93(74.4%)
P2	-	P2	26(20.8%)
P3	07(5.8%)	P3	06(4.8%)
P4	78(62.4%)	P4	-
P5	43(34.4%)	P5	-

Table-2: Age distribution of cases in study group (n=125)

Age of patients	Frequency
20 – 30	11 (8.8%)
31 – 40	42 (33.6%)
41 – 50	51 (40.8%)
51 – 60	21 (16.8%)

Presenting complaints in study cases were low back pain followed by sciatica in 82(65.6%) cases, lower back pain with simultaneous sciatica in 43(34.4%), unilateral radicular pain in 94(75.2%), bilateral radicular pain in 31(24.8%) cases. Right sided radicular pain was present in 42(33.6%) and left sided pain in 52(41.6%) cases. Paresthesia in lower limbs in 46(36.8%) cases while weakness in lower limbs myotomes was noted in 28(22.4%). Mean duration of lower back pain was 6.2 months and for sciatica 2.8 months. Full recovery achieved in 107(85.6%) cases after the procedure.

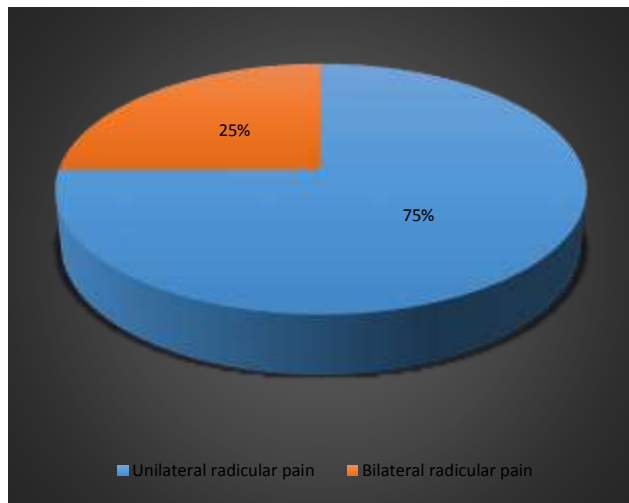


Figure-1: Frequency of radicular pain in study cases

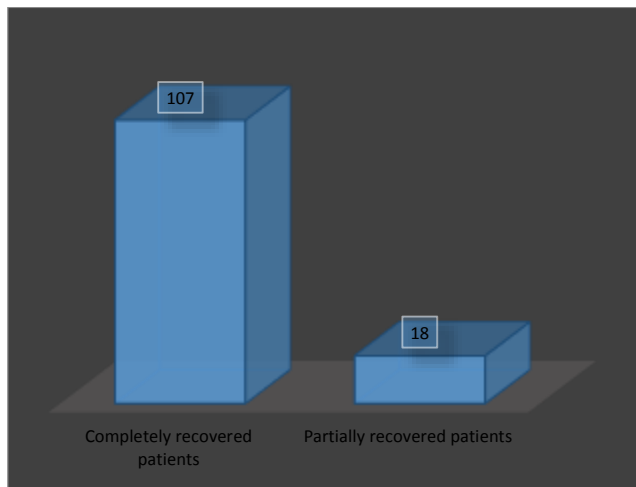


Figure-2: Frequency of fully recovered and partially recovered patients

## DISCUSSION

Lower back pain is a very common problem in our population.<sup>12</sup> Protruded intervertebral disc causes nerve root compression hence developing sciatica in the patients. Early surgical intervention for sciatic pain is more effective than conservative treatment for prolonged period.<sup>13</sup> Ahmed et al reported better results with surgical treatment than conservative management.<sup>14</sup> Standard surgical treatment for protruded disc is excision while there are various methods of excision. Literature suggested that wide laminectomy causes more morbidity and spinal instability than inter-laminar fenestration.<sup>15</sup> In our study fenestration technique has been used in all cases. Dennis pain scale has been used to assess outcomes of the surgery in this study. In our study there were 125 patients including 73(58.4%) males and 52(41.6%) females. Patients with the age of 20-60 years were included in this study with the mean age of 47.3 ± 5.2 years. Most of the cases were between 31-40 years (33.6%) and 41-50 years (40.8%). Most commonly involved disc level was L4-L5 in 77(61.6%) and L5-S1 in 48(38.4%) cases. Unilateral radicular pain was present in 94(75.2%) cases and bilateral pain was present in 31(24.8%) cases. Our results showed that most of the patients in our setups present to orthopedic or neurosurgeons when pain start to change their life style. As most of the population in our country is illiterate and don't have awareness about lower back pain so they take medications from hakeems for long period until their signs symptoms become worse, then they present to the hospitals with advanced disease. Similar findings have been reported in previous studies.<sup>16,17</sup> A study conducted in Pakistan by Sheikh et al reported good results in 84%, and satisfactory results in 16%, while there was no patient with poor results.<sup>18</sup> Previously conducted study in Nepal by Yadav et al reported very good and satisfactory results in 70.6% cases while poor results were noted in 15.7% cases.<sup>19</sup> A study conducted in Iraq reported back pain in 73.7% and lower limb radiating pain in 56.3% cases. Complications reported in their 7.6% cases.<sup>20</sup> Our study has few limitations as it is confined to a limited number of cases and follow up was short. The Operations were performed by various surgeons. These should be randomized controlled clinical trials to obtain better results.

## CONCLUSION

Surgical intervention has better outcomes in selected patients with chronic lower back pain due to protruded intervertebral disc and not responding to conservative management. Fenestration technique for disc excision is a very good and safe technique as it allows complete vision of the nerve roots and complete removal of the protruded disc. This procedure does not require high expertise or special instrumentation.

**Conflict of interest:** No

**Source of funding:** No

## REFERENCES

1. Hamawandi SA, Sulaiman II, Al-Humairi AK. Open fenestration discectomy versus microscopic fenestration discectomy for lumbar disc herniation: a randomized controlled trial. *BMC musculoskeletal disorders*. 2020 Dec;21(1):1-1.
2. Murali SM, Prabhat A, Sundara Rajan T, Arul Jothi V. Outcome following fenestration discectomy among cases with lumbar disc disease. *International Journal of Orthopaedics*. 2019;5(3):318-21.
3. Chandra R, Taxak N, Arora NC, Kakria HL. Management of Prolapse Intervertebral Disc by Lumbar Discectomy by Interlaminar Fenestration—A Review of 30 Patients. *Annals of International Medical and Dental Research*. 2019;5(6):6.
4. Murali SM, Prabhat A, Sundara Rajan T, Arul Jothi V. Outcome following fenestration discectomy among cases with lumbar disc disease. *International Journal of Orthopaedics*. 2019;5(3):318-21.
5. Ma C, Li H, Zhang T, Wei Y, Zhang H, Yu F, Lv Y, Ren Y. Comparison of Percutaneous Endoscopic Interlaminar Discectomy and Open Fenestration Discectomy for Single-Segment Huge Lumbar Disc Herniation: A Two-year Follow-up Retrospective Study. *Journal of Pain Research*. 2022;15:1061.

6. Karthik A. Functional Outcome of Lumbar Fenestration and Discectomy in Patients with Lumbar Intervertebral Disc Prolapse (Doctoral dissertation, Government Mohan Kumaramangalam Medical College, Salem).
7. Lv Z, Jin L, Wang K, Chen Z, Li F, Zhang Y, Lao L, Zhou C, Li X, Shen H. Comparison of effects of PELD and fenestration in the treatment of geriatric lumbar lateral recess stenosis. *Clinical Interventions in Aging*. 2019;14:2187.
8. Xu G, Zhang C, Zhu K, Bao Z, Zhou P, Li X. Endoscopic removal of nucleus pulposus of intervertebral disc on lumbar intervertebral disc protrusion and the influence on inflammatory factors and immune function. *Experimental and therapeutic medicine*. 2020 Jan 1;19(1):301-7.
9. Hussein M, Eladawy A, El-Hewala T. Endoscopic Fenestration in Management of Monosegmental Degenerative Lumbar Spinal Canal Stenosis: A Clinical Cohort Study. *Egyptian Spine Journal*. 2019 Jan 1;29(1):34-45.
10. Massaad E, Rolle M, Hadzipasic M, Kiapour A, Shankar GM, Shin JH. Safety and efficacy of cement augmentation with fenestrated pedicle screws for tumor-related spinal instability. *Neurosurgical Focus*. 2021 May 1;50(5):E12.
11. Zhou W, Hua L, Li M. Wuhan Fourth Hospital, Puai Hospital, Tongji Medical College, Huazhong University of Science and Technology, Hubei Province, China. Key words: transforaminal percutaneous endoscopic lumbar discectomy; lumbar disc herniation: comparison; clinical efficacy; fenestration discectomy. *Invest Clin*. 2019;60(3):204-12.
12. Sheng X, Guo Z, Deng Z, Jiang L, Hu J. Posterior limited unilateral fenestration approach for treating patients with single-segment thoracic and lumbar tuberculosis. *Acta Neurochirurgica*. 2022 Oct;164(10):2637-44.
13. Ahmed T, Rehman L, Akbar R, Javeed F, Akbar S, Gohar R. The Surgical Outcome for Prolapsed Lumbar Intervertebral Disc Based on Visual Analog Scores. *Pakistan Journal Of Neurological Surgery*. 2022 Sep 30;26(3):484-91.
14. Kalhor A, Panezai AS, Hassan S, Javeed F, Rehman L. Clinical Outcome of Fenestration as Minimally Invasive Surgery for Lumbar Disc Herniation: Successes and Obstacles. *Journal of the Dow University of Health Sciences (JDUHS)*. 2021;15(1):23-8.
15. Hassan N, Ahmad M, Ali M, Hassan R, Nawaz S. To Know the Effectiveness of Disc Excision in the Treatment of Herniated Lumbar Intervertebral Disc. *Journal of Gandhara Medical and Dental Science*. 2022 Oct 2;9(4):76-9.
16. KHAN M, ULLAH A, AHMED A, ALI M, AHMAD M. Outcome of Surgical Treatment for Lumbar Disc Herniation Causing Painful Incomplete Foot-Drop. *Pakistan Journal Of Neurological Surgery*. 2020 Oct 1;24(3):283-8.
17. Olby NJ, Moore SA, Brisson B, Fenn J, Flegel T, Kortz G, Lewis M, Tipold A. ACVIM consensus statement on diagnosis and management of acute canine thoracolumbar intervertebral disc extrusion. *Journal of Veterinary Internal Medicine*. 2022 Sep;36(5):1570-96.
18. SHEIKH F, USMANI FA, MALIK H. Outcome of Endoscopic Discectomy in Patients with Lumbar Prolapsed Intervertebral Disc. *Pakistan Journal Of Neurological Surgery*. 2019 Sep 27;23(3):228-33.
19. Yadav RK, Lakhey RB, Paudel S, Kafle D, Pokharel R. Symptomatic improvement and functional outcome of discectomy in Prolapsed Lumbar Intervertebral Disc. *Nepal Orthopaedic Association Journal*. 2020;6(2):5-10.
20. Hamawandi SA, Sulaiman II, Al-Humairi AK. Open fenestration discectomy versus microscopic fenestration discectomy for lumbar disc herniation: a randomized controlled trial. *BMC musculoskeletal disorders*. 2020 Dec;21(1):1-1.