

ORIGINAL ARTICLE

Clinical, Endoscopic and Pathological Characteristics of Colorectal Polyps in Children and Adolescents

MOEEN UL HUQ¹, SAMEEN ARIF SAEED², MUHAMMAD ZAIN AKHTAR³, RIZWAN UR REHMAN⁴, AHMED AFTAB⁵, ROSHEENA AFRIDI⁶

¹Assistant Professor Gastroenterology, Gomal Medical College, Dera Ismail Khan

²House Officer, Pathology, Central Park Teaching Hospital, Lahore

³Post Graduate Resident South Medicine Department, Mayo Hospital, Lahore

⁴District Specialist Gastroenterology, District Headquarter Hospital Kohat Development Authority, Kohat, PAK

⁵House Officer, Medical 'D' Ward, Ayub Teaching Hospital, Abbottabad

⁶Women Medical Officer, Kalsoom Maternity Hospital, Peshawar KPK

Corresponding author: Rizwan ur Rehman, Email: dr.rizwankhattak@yahoo.com

ABSTRACT

Background and Aim: Polyps of the gastrointestinal tract (GI) are apparent protrusions from the mucosal surface. The majority of polyps is asymptomatic and goes unnoticed; however in symptomatic situations, the most common clinical manifestations include abdominal discomfort, and rectal prolapse, intestinal blockage, and GI bleeding. The present study intended to assess the colorectal polyps characteristics based on clinical, pathological, and endoscopy in children and adolescents.

Patients and Methods: This retrospective study was conducted on 78 children and adolescents (<18 years) with colorectal polyps in Gastroenterology Department of DHQ Teaching Hospital and Mufti Mahmood Memorial Hospital, Dera Ismail Khan from January 2020 to September 2022. Participants were assessed for various clinical variables such as age, gender, colonoscopy-related signs and symptoms, polyp identification, symptom's onset age, duration between colonic polyp's endoscopic diagnosis and symptoms onset, and intestinal polyps family history. Polyp's characteristics involved: frequency, histology, morphological type, and distribution. SPSS version 26 was used for data analysis.

Results: The overall mean age was 8.6 ± 2.4 years with an age range 3 to 18 years. Of the total 78 colonic polyps, there were 48 (61.5%) male and 30 (38.5%) females. The most prevalent symptom was rectal bleeding present in 94.6% (n=74) cases with 13.8 ± 16 months. Juvenile was the prevalent polyps found in 76.9% (n=60), out of which 96.7% (n=58) were in left colon. The prevalence of Solitary polyps, multiple polyps, familial adenomatous polyposis, and Peutz-Jeghers syndrome (PJS) was 10.3% (n=8), 6.4% (n=5), 3.8% (n=3), and 2.6% (n=2) respectively. Polyposis syndrome cases were more likely to have old age, diarrhea, anemia, and abdominal pain. Peutz-Jeghers syndrome majority patients experienced intestinal partial blockage with acute episodes, abdominal pain, and emergency laparotomy, resulting in increased morbidity.

Conclusion: The present study found that clinical signs of polyposis syndrome include anemia, diarrhea, abdominal pain, polypectomy history, and older age at presentation. Despite the fact that the most commonly diagnosed kind of polyp was juvenile colonic polyps, the current investigation recognized a substantial number of polyposis syndromes children, which are related with individual's higher rate of morbidity.

Keywords: Colonic polyps, Clinical features, Endoscopic characteristics, Colonoscopy

INTRODUCTION

Gastrointestinal polyps are common due to the preponderance are solitary, localized in the recto sigmoid colon, and have a juvenile hamartomata's histology with a low chance of evolving into a malignant cancer [1]. Nevertheless, as endoscopic procedures have advanced, there has been a shift in understanding of colonic polyps. Histologically, polyps can be classed as neoplastic (benign or malignant) or non-neoplastic (inflammatory or hamartomatous) [2]. Colorectal polyps are one of the most prevalent GI tract disorders in children, presenting as painless rectal bleeding and subsequent anemia. Most polyps are solitary, with no genetic predisposition to neoplasia or long-term risk. Colorectal polyps (>90%) in children are juvenile polyps located in the recto sigmoid colon, but polypectomy with simple sigmoidoscopy may be adequate and efficient therapy [3]. Multiple Adenomatous polyps with recurrence should be identified very away. To avoid neoplastic development in the GI tract, such youngsters may require periodic screening and close supervision [4]. Polyps in the gastrointestinal tract are described as distinct masses of tissue that protrude into the intestine lumen. Distinguishing polyposis syndrome from Solitary Juvenile polyps is critical due to high risk of polyps recurrence associated with polyposis syndrome. Based on histological findings, adenomatous polyps, hamartomas, and juvenile polyps were present in polyposis syndrome, Peutz-Jeghers syndrome, and juvenile polyposis respectively. Unlike solitary juvenile polyps, all of these polyposis syndromes are linked to an elevated risk of colorectal cancer [5, 6].

Multiple polyps in children who underwent a polypectomy colonoscopy were 20% to 50% [7, 8], polyps near the sigmoid colon were 10%-50% [9, 10] and 3%-15% in the right colon [11, 12]. Many juvenile polyps in children, particularly with JPS, are at risk of developing adenomatous changes or even carcinomas in

26%-47% polyp's cases [13, 14]. There is scarcity of data on the polyposis syndrome and symptomatic colorectal polyp's clinical spectrum in Pakistani children and adolescent. In the present study, colorectal polyps in children and adolescent were investigated clinically, colonoscopically, and histopathologically.

METHODOLOGY

This retrospective study was conducted on 78 patients (<18 years) with colorectal polyps in the Gastroenterology Department of DHQ Teaching Hospital and Mufti Mahmood Memorial Hospital, Dera Ismail Khan from January 2020 to September 2022. Participants were assessed for various clinical variables such as age, gender, colonoscopy-related signs and symptoms, polyp identification, symptom's onset age, duration between colonic polyp's endoscopic diagnosis and symptoms onset, and intestinal polyps family history. Polyp's characteristics involved: frequency, histology, morphological type, and distribution. The juvenile hamartomata's polyp's different sub-classification was solitary and multiple polyps. The juvenile polyp's family history presence, polyps along with gastrointestinal tract, and juvenile hamartomatous polyps (five or more) was referred to Juvenile Polyposis syndrome (JPS). Histologically confirmed two or more polyps, positive family history, and typical polyps from histologically confirmed PJS, and mucocutaneous pigmentations were all included in Peutz-Jeghers syndrome (PJS).

SPSS version 26 was used for data analysis. All the categorical variables were expressed as mean and standard deviation. Continuous variables were described as frequency and percentages. Categorical variables were evaluated using the chi-squared test. For non-parametric data, the Mann-Whitney test was used, and for parametric data, the unpaired t test was used; a p-value of 0.05 was considered statistically significant.

RESULTS

The overall mean age was 8.6 ± 2.4 years with an age range 3 to 18 years. Of the total 78 colonic polyps, there were 48 (61.5%) male and 30 (38.5%) females. The most prevalent symptom was rectal bleeding present in 94.6% ($n=74$) cases with 13.8 ± 16 months. Juvenile was the prevalent polyps found in 76.9% ($n=60$), out of which 96.7% ($n=58$) were in left colon. The prevalence of Solitary polyps, multiple polyps, familial adenomatous polyposis, and Peutz-Jeghers syndrome (PJS) was 10.3% ($n=8$), 6.4% ($n=5$), 3.8% ($n=3$), and 2.6% ($n=2$) respectively. Polyposis syndrome cases were more likely to have old age, diarrhea, anemia, and abdominal pain. Peutz-Jeghers syndrome majority patients experienced intestinal partial blockage with acute episodes, abdominal pain, and emergency laparotomy, resulting in increased morbidity. Figure-1 depicts the gender's distribution. Prevalence of different polyps are demonstrated in Figure-2. Age-wise distribution of patients are shown in Figure-3.

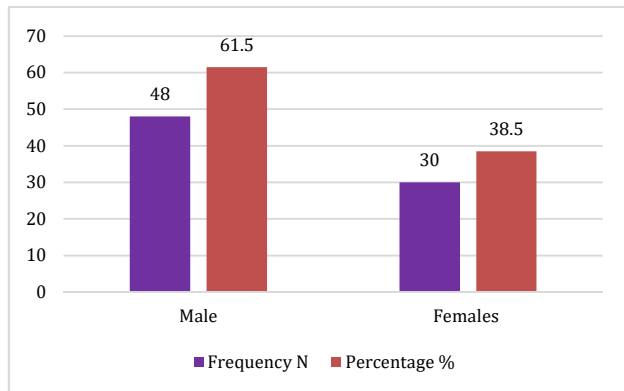


Figure-1: Gender's distribution ($n=78$)

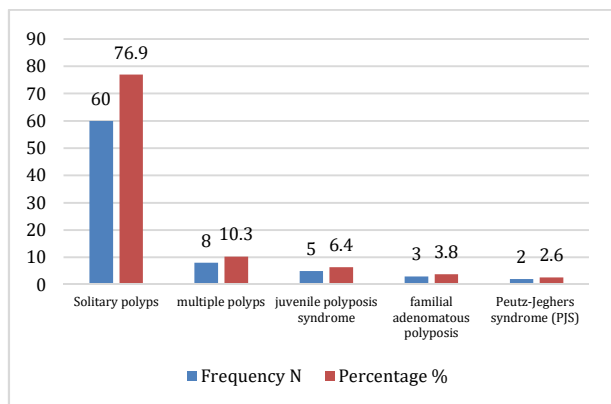


Figure-2: Prevalence of different polyps ($n=78$)

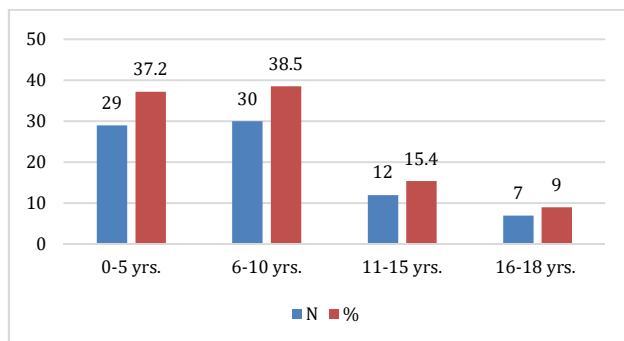


Figure-3: Age-wise distribution of patients ($n=78$)

DISCUSSION

The present study mainly investigated the colorectal polyps clinical, endoscopic, and pathological characteristics and found that the most common polyps were juvenile, followed by solitary polyps, multiple polyps, familial adenomatous polyposis, and Peutz-Jeghers disease. Anemia, diarrhea, abdominal pain, a history of polypectomy, and an older age at presentation are all clinical symptoms of polyposis syndrome. Despite the fact that the most usually diagnosed kind of polyp was juvenile colonic polyps, the current study found a considerable number of polyposis syndromes cases among children, which are related with a higher risk of morbidity in individuals. In our study, benign juvenile polyps were the most prevalent colorectal polyps. Males are more susceptible to benign juvenile polyps than in girls and generally manifest as painless rectal bleeding [15, 16]. According to our findings, mostly patients suffer from juvenile polyps within 10 years of life. These polyps are typically seen alone in the recto sigmoid colon [17]. Several studies, however, have found that multiple polyps and sigmoid colon proximal varied from 53% to 58% and 30% to 60% respectively [18-20]. As a result, in all children with polyps, a comprehensive colonoscopy evaluation is required [21].

In our study, 10.3% of the children had numerous polyps, with 6.4% having lesions near the sigmoid colon. Another study reported that multiple polyps and recto sigmoid colon was found in 24% and 85% children [22]. According to Min et al. [23], adenomatous transformation occurs in up to 47% of adolescent polyposis patients. Adenomatous transition was identified in two of eight individuals with adolescent polyposis (25%).

A new studies conducted on Chinese children [24] reported that 94.9%, hamartomatous polyps had juvenile polyps, adenomatous and hyperplastic polyps and inflammatory polyps. Wang et al. investigated the 29 polyps among 730 colonoscopies, out of which 24 were juvenile, Peutz-Jeghers 2, and adenomatous in 1 [25]. Recurrence of juvenile polyps following polypectomy is uncommon (1.7%) [26]. In our analysis, 4.7% of patients with juvenile polyps had a history of polypectomy, which is similar to the 4.5% identified by Hazewinkel et al. [27].

Polyps were limited to the left colon was found non-polyposis group and polyposis syndrome group was 96.7% and none. This research was comparable to that of East et al. [28]. In addition, Hoffenberg group similarly reported that anemia, sessile polyposis, and pedunculated was more like to be found in the polyposis syndrome group as compared to the non-polyposis group. Though, a substantial variations in both groups in terms of duration of symptom, age of presentation, stomach discomfort presence, and polypectomy history [29].

Within the pediatric age range, patients with PAF were asymptomatic, with only a few symptomatic instances before the twenties [30], the major manifestation arises in terms of rectal bleeding, trailed by stomach discomfort, diarrhea, and anemia. Benign extra colonic symptoms such as retina congenital enlargement, osteomas, and epidermoid cysts are conceivable [31], as demonstrated by the current case series. Tumors of the desmoid may be seen in 10%-15% of PAF patients [32].

CONCLUSION

The present study found that clinical signs of polyposis syndrome include anemia, diarrhea, abdominal pain, polypectomy history, and older age at presentation. Despite the fact that the most commonly diagnosed kind of polyp was juvenile colonic polyps, the current investigation recognized a substantial number of polyposis syndromes children, which are related with individual's higher rate of morbidity.

REFERENCES

1. Rath C, Ingle M, Pandav N, Pipaliya N, Choksi D, Sawant P. Clinical, endoscopic, and pathologic characteristics of colorectal polyps in Indian children and adolescents. *Indian Journal of Gastroenterology*. 2015 Nov;34(6):453-7.

2. Kim JY, Bin Kim Y, Choi S, Lee YM, Kim HJ, Kim SC, Jang HJ, Choi SY, Yi DY, Lee Y, Choi YJ. Associations of polyp characteristics in children and adolescents presenting with less than five colorectal polyps: a full colonoscopy is still required. *Gut and Liver*. 2022.
3. Ibrahim N, Septer SS, Lee BR, Garola R, Shah R, Attard TM. Polyp characteristics of nonsyndromic and potentially syndromic juvenile polyps: a retrospective cohort analysis. *Journal of pediatric gastroenterology and nutrition*. 2019 Dec;69(6):668.
4. Dipasquale V, Romano C, Iannelli M, Tortora A, Princiotta A, Ventimiglia M, Melita G, Pallio S. The management of colonic polyps in children: a 13-year retrospective study. *European Journal of Pediatrics*. 2021 Jul;180(7):2281-6.
5. Kay M, Eng K, Wyllie R. Colonic polyps and polyposis syndromes in pediatric patients. *Curr Opin Pediatr* 2015;27:634-641.
6. Latchford A, Cohen S, Auth M, et al. Management of Peutz-Jeghers syndrome in children and adolescents: a position paper from the ESPGHAN Polyposis Working Group. *J Pediatr Gastroenterol Nutr* 2019;68:442-452.
7. Thakkar K, Alsarraj A, Fong E, Holub JL, Gilger MA, El Serag HB. Prevalence of colorectal polyps in pediatric colonoscopy. *Dig Dis Sci* 2012;57:1050-1055.
8. Cohen S, Hyer W, Mas E, et al. Management of juvenile polyposis syndrome in children and adolescents: a position paper from the ESPGHAN Polyposis Working Group. *J Pediatr Gastroenterol Nutr* 2019;68:453-462.
9. Lee YJ, Park JH. The most common cause of lower gastrointestinal bleeding without other symptoms in children is colonic polyp: is total colonoscopy needed? *Clin Endosc* 2019;52:207-208.
10. Hao Y, Wang Y, Qi M, He X, Zhu Y, Hong J. Risk factors for recurrent colorectal polyps. *Gut Liver* 2020;14:399-411.
11. Gupta V, East JE. Optimal endoscopic treatment and surveillance of serrated polyps. *Gut Liver* 2020;14:423-429.
12. Das SR, Karim AS, Rukonuzzaman M, et al. Juvenile polyps in Bangladeshi children and their association with fecal calprotectin as a biomarker. *Pediatr Gastroenterol Hepatol Nutr* 2022;25:52-60.
13. Poles GC, Clark DE, Mayo SW, et al. Colorectal carcinoma in pediatric patients: a comparison with adult tumors, treatment and outcomes from the National Cancer Database. *J Pediatr Surg* 2016; 51:1061–1066.
14. Buijs MM, Steele RJC, Buch N, et al. Reproducibility and accuracy of visual estimation of polyp size in large colorectal polyps. *Acta Oncol* 2019; 58 (sup 1):S37–S41.
15. Pham T, Bajaj A, Berberi L, et al. Mis-sizing of adenomatous polyps is common among endoscopists and impacts colorectal cancer screening recommendations. *Clin Endosc* 2018; 51:485–490.
16. Levene Y, Hutchinson JM, Tinkler-Hundal E, et al. The correlation between endoscopic and histopathological measurements in colorectal polyps. *Histopathology* 2015; 66:485–490.
17. Silbermintz A, Matar M, Assa A, Zevit N, Glassberg YM, Shamir R (2019) Endoscopic findings in children with isolated lower gastrointestinal bleeding. *Clin Endosc* 52:258–261. <https://doi.org/10.5946/ce.2018.046>.
18. Sahn B, Bitton S (2016) Lower gastrointestinal bleeding in children. *Gastrointest Endosc Clin N Am* 26:75–98. <https://doi.org/10.1016/j.giec.2015.08.007>.
19. Di Nardo G, Esposito F, Ziparo C, Strisciuglio C, Vassallo F, Di Serafino M et al (2020) Faecal calprotectin and ultrasonography as non-invasive screening tools for detecting colorectal polyps in children with sporadic rectal bleeding: a prospective study. *Ital J Pediatr* 46:66. <https://doi.org/10.1186/s13052-020-00828-1>.
20. Kay M, Wyllie R (2020) Pediatric colonoscopic polypectomy technique. *J Pediatr Gastroenterol Nutr* 70:280–284. <https://doi.org/10.1097/MPG.0000000000002591>.
21. Olafsdottir I, Nemeth A, Lörinc E, Toth E, Agardh D (2016) Value of fecal Calprotectin as a biomarker for juvenile polyps in children investigated with colonoscopy. *J Pediatr Gastroenterol Nutr* 62:43–46. <https://doi.org/10.1097/MPG.0000000000000893>.
22. Andrade DO, Ferreira AR, Bittencourt PF, Ribeiro DF, Silva RG, Alberti LR (2015) Clinical, epidemiologic, and endoscopic profile in children and adolescents with colonic polyps in two reference centers. *Arq Gastroenterol* 52:303–310.
23. Min YW, Lee JH, Lee SH, et al. Prevalence of proximal colon serrated polyps in a population at average risk undergoing screening colonoscopy: a multicenter study. *Clin Res Hepatol Gastroenterol*. 2012;36:604–608. doi: 10.1016/j.clinre.2011.12.016.
24. Leung WK, Tang V, Lui PC. Detection rates of proximal or large serrated polyps in Chinese patients undergoing screening colonoscopy. *J Dig Dis*. 2012;13:466–471. doi: 10.1111/j.1751-2980.2012.00621.x.
25. Pohl H, Srivastava A, Bensen SP, et al. Incomplete polyp resection during colonoscopy—results of the complete adenoma resection (CARE) study. *Gastroenterology*. 2013;144:74–80. doi: 10.1053/j.gastro.2012.09.043.
26. East JE, Vieth M, Rex DK. Serrated lesions in colorectal cancer screening: detection, resection, pathology and surveillance. *Gut*. 2015;64:991–1000. doi: 10.1136/gutjnl-2014-309041.
27. Hazewinkel Y, López-Cerón M, East JE, et al. Endoscopic features of sessile serrated adenomas: validation by international experts using high-resolution white-light endoscopy and narrow-band imaging. *Gastrointest Endosc*. 2013;77:916–924. doi: 10.1016/j.gie.2012.12.018.
28. East JE, Atkin WS, Bateman AC, et al. British Society of Gastroenterology position statement on serrated polyps in the colon and rectum. *Gut*. 2017;66:1181–1196. doi: 10.1136/gutjnl-2017-314005.
29. Ma MX, Bourke MJ. Sessile serrated adenomas: how to detect, characterize and resect. *Gut Liver*. 2017;11:747–760. doi: 10.5009/gnl16523.
30. Hurt C, Ramaraj R, Farr A, et al. Feasibility and economic assessment of chromocolonoscopy for detection of proximal serrated neoplasia within a population-based colorectal cancer screening programme (CONSCOP): an open-label, randomised controlled non-inferiority trial. *Lancet Gastroenterol Hepatol*. 2019;4:364–375. doi: 10.1016/S2468-1253(19)30035-4.
31. Repici A, Wallace MB, East JE, et al. Efficacy of per-oral methylene blue formulation for screening colonoscopy. *Gastroenterology*. 2019;156:2198–2207. doi: 10.1053/j.gastro.2019.02.001.
32. Baek MD, Jackson CS, Lunn J, et al. Endocuff assisted colonoscopy significantly increases sessile serrated adenoma detection in veterans. *J Gastrointest Oncol*. 2017;8:636–642. doi: 10.21037/jgo.2017.03.07.