

## ORIGINAL ARTICLE

# Imaging Characteristics of Retinoblastoma: A Single Tertiary Care Center Experience from Pakistan

MARYA HAMEED<sup>1</sup>, FATIMA SIDDIQUI<sup>1</sup>, ASHOK KUMAR<sup>1</sup>, SAMRA SALEEM<sup>1</sup>, HINAHANIF<sup>1</sup>, WAJID HUSSAIN<sup>2</sup>, HAYAT BOZDAR<sup>3</sup>

<sup>1</sup>Department of Radiology, National Institute of Child Health, Karachi

<sup>2</sup>Department of Pediatrics, National Institute of Child Health, Karachi

<sup>3</sup>Department of Infectious Disease, National Institute of Child Health, Karachi

Correspondence to Dr. Fatima Siddiqui, Email: [siddiquifatima198@gmail.com](mailto:siddiquifatima198@gmail.com)

## ABSTRACT

**Background:** Retinoblastoma is a rare tumor of eye in the pediatric population. It is seen in every 15000-18000 births with no gender or racial predilection. Retinoblastoma can have a variable presentation ranging from leukocoria to a mass in the eye.

**Aim:** To provide physicians a snapshot of different modes of presentation. This study employs the data from computed tomography (CT) and magnetic resonance imaging (MRI) and analyzing it for frequency of different presentations from a radiological point of view.

**Methods:** This was a retrospective cross-sectional study carried out at the National Institute of Child Health (NICH) which is the largest tertiary care pediatric center in Karachi, Pakistan. Records of children from 1 month to 16 years who were diagnosed with retinoblastoma between March 2021 to March 2022 were accessed from the database and assessed. The collected data was then analyzed on SPSS 26.

**Results:** The most frequent presentation noted was leukocoria followed by vision loss, swelling, pain and redness. Calcification was the most frequently reported feature in CT scan whereas retroglobular involvement was mostly seen in MRI scans. Chi square showed a statistically significant correlation between age at presentation with presenting symptoms ( $p=0.04$ ) and sellar involvement ( $p=0.00$ ). Additionally, statically significant association was seen between family history and laterality in our study.

**Conclusion:** MRI is the recommended modality due to its sensitivity and superior soft-tissue resolution. CT scan is superior to MRI in detecting calcifications. In developing countries due to a lack of proper facilities and awareness, there is a disparity in the prognosis and presentation of retinoblastoma. Bilateral tumors are most commonly heritable and patients presenting with tumors in both eyes are recommended a through genetic workup.

**Keywords:** Retinoblastoma, ocular tumor, leukocoria, red eye, Magnetic resonance imaging, computed tomography

## INTRODUCTION

Retinoblastoma is a relatively rare ocular tumor of children which is considered to be the most common intraocular cancer in infancy as well as childhood. The incidence of retinoblastoma is estimated to be 1 in every 15000 to 18000 births and shows no racial or gender predilection. The incidence of retinoblastoma has a geographical asymmetry and it is more prevalent in developing regions of Africa and Asia<sup>1</sup>. It is associated with mutations in the retinoblastoma gene (Rb) which can also be inherited from generation to generation in an autosomal dominant pattern. The heritable retinoblastoma constitutes about 30-40% of all diagnoses made<sup>2</sup>. Mainly the diagnosis of retinoblastoma is based on clinical findings, nonetheless, the importance of sophisticated imaging techniques such as magnetic resonance imaging and computed tomography scan cannot be understated as they are highly sensitive in assessing intraocular extension and optic nerve invasion of the tumor along with detection of pineal malignancy, especially in patients with the heritable retinoblastoma<sup>1,3</sup>. Ultrasound is also used to detect abnormal masses with calcifications and it detects 92-95% calcifications which are confirmed through histopathology<sup>4,5</sup>. Retinal detachment can also be seen which is an important finding for defining tumor growth patterns which can be either endophytic or exophytic or even a combination of the two. Regardless of the advantages of ultrasound it is still not recommended to evaluate the metastatic risk factors which carry a high prognostic value and also because of the obscuration of the optic nerve due to the calcifications<sup>6</sup>. CT scans are effective in the determination of tumor growth. CT scans are considered to be a reliable modality to detect calcifications and have a sensitivity of 81-96% and even higher specificity<sup>7</sup>. Historically, CT was the first method to detect optic nerve invasion however as new evidence emerged it revealed it to have a low sensitivity<sup>8</sup>. Findings such as the choroid and sclera infiltration and extension of tumor into the optic nerve beyond the cribriform plate are not reliably observed on it<sup>9</sup>.

Received on 19-07-2022

Accepted on 23-11-2022

MRI, on the other hand, has a superior soft tissue imaging capability and is more sensitive and specific in detecting several of the above-mentioned prognostic factors. MR imaging employing high resolution is highly recommended by the guidelines and is the most accurate and reliable modality in the pretreatment staging without having any considerable side effect profile<sup>9</sup>.

## METHOD

This descriptive, retrospective cross-sectional study was conducted at National Institute of Child Health with collaboration between department of radiology and department of pediatric oncology. This study was approved by the institutional ethical review board of our hospital (No. IRB Ex 06/2022). The retrospective data was collected from patient records dated from March 2021 to March 2022 through hospital records. Only the patients with retinoblastoma who were diagnosed in our hospital in the selected time frame were considered eligible whereas patients diagnosed at any other center but having treatment in the NICH were excluded. A proforma with details of retinoblastoma imaging features was filled out by investigators through patient records.

All quantitative and qualitative variables including age, gender, tumor characteristics, CT findings, MRI findings were recorded analyzed on SPSS version 26. Descriptive statistics were calculated; chi square test was applied and  $p$ -value  $< 0.05$  was considered as statistically significant.

## RESULTS

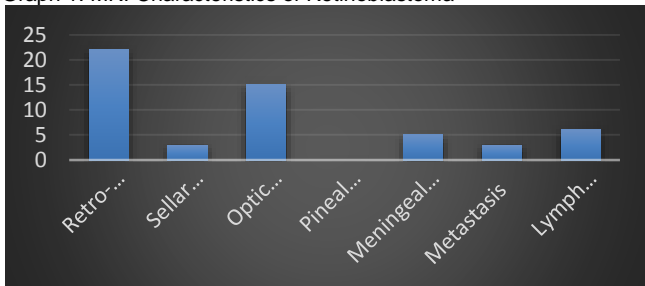
A total number of 32 patients were reported in our center in the study period. In our analysis (Table 1) we found that most patients reported were under the age of 5 (68.75) with only 1 patient (3.12) diagnosed after the age of 10. The most common presenting complaint was leukocoria (37.5) followed by swelling (28.12), pain (21.87), and redness (9.37). One-third of the patients were presented with unilateral retinoblastoma. In the CT scans calcification was found in 37 patients (84.7%), the endophytic

tumor was in 11(34.3%), exophytic 21(65.6%), and proptosis in 17 patients (53.1%). In the MRI results, we found 22(68.7%) patients with retroglobular involvement, 3(9.3%) with sellar involvement, 15(46.8%) with optic nerve invasion, and meningeal involvement was found in 5(16.1%) patients, 3(9.3%) patients had distant metastasis whereas metastatic lymph nodes were in 6(18.75%) of the patients. No pineal region involvement was seen in any participant. Chi square showed a statistically significant correlation between age at presentation with presenting symptoms (p=0.04) and sellar involvement (p=0.00). Additionally, statistically significant association was seen between family history and laterality in our study. (p=0.02) There was no significant association seen between gender and any of the presenting symptoms or imaging findings.

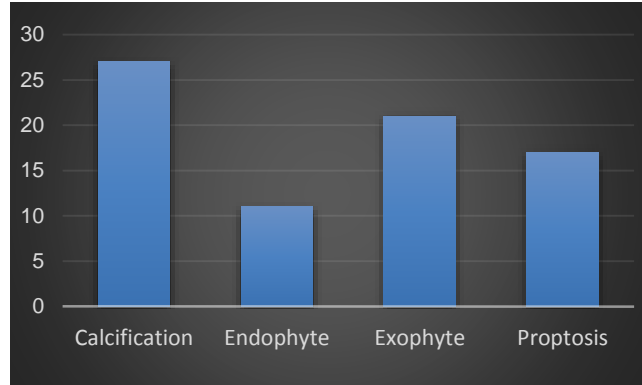
Table 1:

Characteristic	Frequency (n) (%)
Age (years)	0 – 5: 22 (68.75) 6 – 10: 9 (28.12) 11-15: 1 (3.12)
Gender	Male: 20 (62.5) Female: 12 (37.5)
Presenting Complain	Leukocoria: 12(37.5) Vision Loss: 4 (12.5) Swelling: 9 (28.12) Pain: 7 (21.87) Redness: 3 (9.37) Haziness: 1 (3.12)
Unilateral or Bilateral	Unilateral: 24 (75) Bilateral: 8 (25)
Family History	10(31.2)
Calcification	27 (84.7)
Endophyte	11 (34.3)
Exophyte	21 (65.6)
Proptosis	17 (53.1)
Retro-globular Involvement	22 (68.7)
Sellar Involvement	3 (9.3)
Optic Nerve Involvement	15 (46.8)
Pineal Region Involvement	0
Meningeal Involvement	5 (16.1)
Metastasis	3 (9.3)
Lymph Nodes	6(18.75)

Graph 1. MRI Characteristics of Retinoblastoma



Graph 2. CT Characteristics of Retinoblastoma



## DISCUSSION

Retinoblastoma is the most common intraocular neoplasm in the pediatric age group worldwide with an incidence rate of 1 in every 15000-20000 live birth which corresponds to almost 9000 cases in a single year<sup>(10)</sup>. In the last century, significant advancements have been made in therapies and diagnostic methods which have dramatically increased the survival and diagnostic accuracy of retinoblastoma. There is a major disparity in the outcomes of retinoblastoma in developed and developing countries which is a troubling sign. Poorer outcomes are frequently seen in countries where targeted therapies are not yet established because of various reasons such as technological, social, and economical obstacles<sup>11</sup>.

The majority of the cases in our analysis were under the age of 5(68.5%) which is in agreement with a nationwide analysis where the average age was estimated to be 35.98±27.63 months<sup>12</sup>. The average presentation varies globally which could be due to a difference in diagnostic precision and a national awareness level causing a disparity. In Pakistan, the presentation is delayed as compared to India where it is 23.98 months<sup>10</sup>. The most common presenting complaint in our study is leukocoria with around 37.5% of the patients presented with this finding. In Africa and some parts of Asia, proptosis and a fungating mass is also a common presentation. Proptosis becomes a more frequent finding with the increasing age due to delayed diagnosis resulting in an extraocular extension. It has been hypothesized that delayed diagnosis in older children is potentially due to the anterior location of the tumor in contrast to the posterior location in younger children causing signs of leukocoria thereby enabling early tumor detection. A study employing CT scan for detection of retinoblastoma features found proptosis in 32.8% of patients which is significantly lower than in developed countries such as the USA (0.5%), South Korea (1.4%), and Australia where there was no proptosis seen. These contrasting findings could be attributed to advanced diagnostic methods and early intervention<sup>13</sup>. In our study, swelling (28.12%), pain (21.87%), and redness (9.37%) were the other common presentations. Bilateral eye involvement was seen in 25% of our patients and previously data has shown that bilateral involvement is most commonly heritable form of retinoblastoma and similarly our study showed a significant correlation between positive family history and bilateral retinoblastoma, therefore it is recommended to obtain a thorough family history in patients who present with both eyes involved. Additionally, siblings' history and genetic workup should also be advised which could aid in early diagnosis to avoid dreadful consequences of this tumor<sup>14</sup>.

MRI is highly accurate in detecting tumor extension and is often used as a guidance tool for further treatment. It has become a widely used modality for imaging workup because of a superior soft-tissue resolution and no use of ionizing radiation which could cause a secondary malignancy. The detection accuracy of optic nerve invasion through MRI is said to vary with respect to the severity and extent of invasion<sup>(15)</sup>. In our analysis, we found that 46.8% of the patients had optic nerve invasion which is an

important prognostic factor as mortality rates are directly influenced by it. The limitation of MRI can be due to the anatomy of the intraocular optic nerve head with accompanied neural and vascular elements which have their greatest length of approximately 1mm which coincides with the lower limits of MRI resolution.

Delayed diagnosis in developing countries causes the tumor to metastasize in extraocular locations especially the central nervous system due to the anatomical proximity. MRI is considered to be helpful in the detection of intracranial extension and also to gauge the treatment response. The analysis of CNS metastasis of retinoblastoma by Hu et al showed that 38.7% of them have meninges which are in contrast to our findings of 16.7 % meningeal involvement<sup>16</sup>.

Despite MRI being the modality of choice for imaging visual pathways in children, CT scan remains the imaging of choice for detecting intraocular calcification which is an integral finding in retinoblastoma. CT scanning has disadvantages of resolution and iodinated contrast but it is the most specific modality for calcification due to the diamagnetic properties of calcium. In the analysis done by Galluzzi et al, it was estimated that when putting together ophthalmoscopy, ultrasonography, and MR imaging data, no calcification detected by CT scans was missed making it a highly specific modality<sup>(4)</sup>. In our analysis, we found that 84.37% of the patients had calcifications and all of them were in line with the biopsy findings.

Clinical trials are considered to be the gold standard treatment for patients with retinoblastoma. Due to relatively lower number of cases, not many clinical trials have been completed. The literature suggests that most of the trials have patients from high income countries and middle-income countries are not widely represented with the lower income countries not having any trials investigating treatment of retinoblastoma. The systemic chemotherapy is the mainstay for retinoblastoma which primarily consists of carboplatin, vincristine and etoposide. According to The Toronto Protocol high dose chemotherapy and high dose short duration cyclosporine is combined to tackle multidrug resistance with avoidance of toxicities. As it is an aggressive malignancy, initial responses cannot be relied upon for control of disease. Initial chemotherapy is supplemented with laser treatment and cryotherapy<sup>17</sup>. Previously external beam radiotherapy was incorporated to salvage the globe. In today's era it is not much used due to associated side-effects and better outcomes with the chemotherapy. Despite the advances it still holds relevance to control extra-ocular extension, recurrence and positive optic nerve margins following enucleation. Combining radiotherapy with intra-vitreous chemotherapy can achieve a satisfactory disease control in 71% of patients<sup>18</sup>. Despite advances in the management with newer therapies being discovered, enucleation of the globe still remains treatment of choice in the modern world. It is mainly employed for massive tumors, tumors complicated with vitreous hemorrhage, extraocular extension, optic nerve invasion or in cases where previous therapies failed and all options have been exhausted. The management of retinoblastoma relies upon follow up. The family of the patient should be advised for a RB1 mutation and counseling should also be done on the implications of those results and their potential effects on their lives. Patients are also monitored for a long period and preferably for life. Proper surveillance for disease and secondary complications of treatment requires frequent ophthalmology visits with detailed examination of the unaffected eye so that in case of recurrence a timely diagnosis and treatment can be initiated<sup>18</sup>.

The limitations of our study include a smaller sample size which could be in part due to this being a single-center study. This topic warrants a more in-depth study where city-wide samples are studied for imaging characteristics that would give a snapshot of presentation and could also help gauge the utility of imaging techniques for retinoblastoma. This topic can also be approached with a study where a detailed analysis of radiological features and

its relationship to outcomes with long term follow-up after treatment can be carried out.

## CONCLUSION

Retinoblastoma is the most common intraocular malignancy of the childhood. The prognosis of this malignancy relies on a timely diagnosis. The most common mode of presentation of retinoblastoma is leukocoria followed by vision loss, swelling, and pain. Bilateral tumors are most commonly heritable and patients presenting with tumors in both eyes are recommended a through genetic workup. CT scan and MRI are the widely used imaging modalities. MRI is the recommended modality due to its sensitivity and superior soft-tissue resolution. CT scan is superior to MRI in detecting calcifications. In developing countries due to a lack of proper facilities and awareness, there is a disparity in the prognosis and presentation of retinoblastoma which could be tackled effectively by improving knowledge and enhancing diagnostic accuracy.

**Conflict of interest:** Nil

## REFERENCES

- Rao R, Honavar SG. Retinoblastoma. *Indian J Pediatr.* 2017;84:937-944. doi: 10.1007/s12098-017-2395-0..
- Nichols KE, Walther S, Chao E, Shields C, Ganguly A. Recent advances in retinoblastoma genetic research. *Curr Opin Ophthalmol.* 2009;20:351-5. doi: 10.1097/ICU.0b013e32832f7f25.
- Rootman DB, Gonzalez E, Mallipatna A, Vandenhoven C, Hampton L, Dimaras H, Chan HS, Gallie BL, Heon E. Hand-held high-resolution spectral domain optical coherence tomography in retinoblastoma: clinical and morphologic considerations. *Br J Ophthalmol.* 2013;97:59-65. doi: 10.1136/bjophthalmol-2012-302133.
- Galluzzi P, Hadjistilianou T, Cerase A, De Francesco S, Toti P, Venturi CJAJoN. Is CT still useful in the study protocol of retinoblastoma? *AJNR Am J Neuroradiol* 2009;30:1760-5. doi: 10.3174/ajnr.A1716
- Roth DB, Scott IU, Murray TG, Kaiser PK, Feuer WJ, Hughes JR, Rosa RH Jr. Echography of retinoblastoma: histopathologic correlation and serial evaluation after globe-conserving radiotherapy or chemotherapy. *J Pediatr Ophthalmol Strabismus.* 2001;38:136-43. doi: 10.3928/0191-3913-20010501-06.
- Kaste SC, Jenkins JJ 3rd, Pratt CB, Langston JW, Haik BG. Retinoblastoma: sonographic findings with pathologic correlation in pediatric patients. *AJR Am J Roentgenol.* 2000 Aug;175:495-501. doi: 10.2214/ajr.175.2.1750495.
- Beets-Tan RG, Hendriks MJ, Ramos LM, Tan KE. Retinoblastoma: CT and MRI. *Neuroradiology.* 1994;36:59-62. doi: 10.1007/BF00599199.
- Brisse HJ, Guesmi M, Aerts I, Sastre-Garau X, Savignoni A, Lumbroso-Le Rouic L, Desjardins L, Doz F, Asselain B, Bours D, Neuenschwander S. Relevance of CT and MRI in retinoblastoma for the diagnosis of postlaminar invasion with normal-size optic nerve: a retrospective study of 150 patients with histological comparison. *Pediatr Radiol.* 2007 Jul;37:649-56. doi: 10.1007/s00247-007-0491-4. Epub 2007 May 4.
- de Graaf P, Görnicke S, Rodjan F, Galluzzi P, Maeder P, Castellijn JA, Brisse HJ; European Retinoblastoma Imaging Collaboration (ERIC). Guidelines for imaging retinoblastoma: imaging principles and MRI standardization. *Pediatr Radiol.* 2012;42:2-14. doi: 10.1007/s00247-011-2201-5. Epub 2011 Aug 18.
- Jain M, Rojanaporn D, Chawla B, Sundar G, Gopal L, Khetan V. Retinoblastoma in Asia. *Eye (Lond).* 2019 Jan;33:87-96. doi: 10.1038/s41433-018-0244-7..
- Chawla B, Kumar K, Singh AD. Influence of Socioeconomic and Cultural Factors on Retinoblastoma Management. *Asia Pac J Oncol Nurs.* 2017;4:187-190. doi: 10.4103/apjon.apjon\_19\_17.
- Adhi MI, Kashif S, Muhammed K, Siyal N. Clinical pattern of Retinoblastoma in Pakistani population: Review of 403 eyes in 295 patients. *J Pak Med Assoc.* 2018 ;68:376-380.
- Reddy SC, Anusya S. Clinical presentation of retinoblastoma in Malaysia: a review of 64 patients. *Int J Ophthalmol.* 2010;3:64-8. doi: 10.3980/ij.issn.2222-3959.2010.01.15.
- Ishaq H, Patel BC. Retinoblastoma. [Updated 2022 Aug 8]. In: StatPearls [Internet]. Treasure Island (FL): StatPearls Publishing; 2022 Jan-. Available from: <https://www.ncbi.nlm.nih.gov/books/NBK545276/>
- Hiasat JG, Saleh A, Al-Hussaini M, Al Nawaiseh I, Mehyar M, Qandeel M, Mohammad M, Deebajah R, Sultan I, Jaradat I, Mansour A, Yousef YA. The predictive value of magnetic resonance imaging of retinoblastoma for the likelihood of high-risk pathologic features. *Eur J Ophthalmol.* 2019 Mar;29:262-268. doi: 10.1177/1120672118781200.
- Hu H, Zhang W, Wang Y, Huang D, Shi J, Li B, Zhang Y, Zhou Y. Characterization, treatment and prognosis of retinoblastoma with central nervous system metastasis. *BMC Ophthalmol.* 2018;23:18:107. doi: 10.1186/s12886-018-0772-8.

17. Dimaras H, Kimani K, Dimba EA, Gronsdahl P, White A, Chan HS, Gallie BL. Retinoblastoma. *Lancet*. 2012;14;379:1436-46. doi: 10.1016/S0140-6736(11)61137-9..18. Ancona-Lezama D, Dalvin LA, Shields CL. Modern treatment of retinoblastoma: A 2020 review. *Indian J Ophthalmol*. 2020;68:2356-2365. doi: 10.4103/ijo.IJO\_721\_20.
18. Guo J, Qin S, Liang J, Lin T, Si L, Chen X, Chi Z, Cui C, Du N, Fan Y, Gu K, Li F, Li J, Li Y, Liang H, Liu J, Lu M, Lu A, Nan K, Niu X, Pan H, Ren G, Ren X, Shu Y, Song X, Tao M, Wang B, Wei W, Wu D, Wu L, Wu A, Xu X, Zhang J, Zhang X, Zhang Y, Zhu H; written; Chinese Society of Clinical Oncology (CSCO) Melanoma Panel. Chinese Guidelines on the Diagnosis and Treatment of Melanoma (2015 Edition). *Ann Transl Med*. 2015;3:322. doi: 10.3978/j.issn.2305-5839.2015.12.23.