

# Mammography and Ultrasonography as Screening Tools for the Early Detection of Breast Cancer – A Review

ZAHRA BAKHTIARI, MOHAMMAD GHASEM HANAFI\*

Department of Radiology, Emam Hospital, Ahvaz Jundishapur University of Medical Sciences, Ahvaz, Iran  
Correspondence to: Dr. Mohammad Ghasem Hanafi, E-mail: gaseghanafi@yahoo.com

## ABSTRACT

Breast cancer is the most prevalent form of cancer among women in the world and its incidence is increasing in Iranian women. According to the literature, breast cancer is the second leading cause of cancer deaths in women, therefore it is considered as an important medical and social issue. Early detection of breast cancer, will lead to easier and more effective treatment, therefore with timely diagnosis and treatment, this fatal disease will become a treatable disease. The underlying theory here is that early diagnosis and treatment of the disease will reduce complications and costs and improve the prognosis of the disease. Attempts to the early detection of this type of cancer have led to the use of a variety of screening programs. In recent years, screening methods such as mammography and ultrasound have improved the survival of patients with early detection of breast cancer. Mammography is the standard method to screening of breast cancer, but in cases where breast tissue density is high in mammography, it is advisable to evaluate patients with other imaging modalities, such as ultrasound. However, the sensitivity and specificity of mammography and sonography are varying across different studies. Combined imaging methods can provide supplementary information to improve staging and therapy planning. In this review article we summarize imaging technologies such as mammography and ultrasonography as well as their applications for the management of breast cancer patients. Because it seems that one of the ways to prevent the complications of breast cancer is timely diagnosis and treatment of this disease.

**Keywords:** breast cancer, mammography, ultrasonography

---

## INTRODUCTION

Breast cancer, as the most common malignant disease in women worldwide, accounts for 24.2% of all new cancer cases, and accounts for 15% of all cancer-related deaths among women<sup>1</sup>. In 2018, approximately 2.1 million new breast cancer cases and 626,679 deaths were reported<sup>2</sup>. In Iran, breast cancer is the most common cancer in women with the incidence of crude and standardized age of 17.4 and 21.3 per 100,000 respectively<sup>3</sup>. The age of breast cancer in Iranian women is 10 years lower than in western women, due to the higher density of breast tissue in Iranian women than other races<sup>4,5</sup>. Early detection of this cancer will lead to easier and more effective treatment. Therefore, this fatal disease will become a treatable disease with timely diagnosis and treatment. In developing countries, due to lack of training and facilities, more than 30 to 80 percent of patients cannot be diagnosed in early stage, but in industrialized countries 50% of breast cancer are diagnosed when they are still limited and have not spread. Surveys show that the survival rate of women with early detection of breast cancer is 90%, however, this rate is reduced by 60% for women with the developed disease<sup>6</sup>. Early detection of breast cancer, when it is most treatable is the key factor in the reduction of mortality and cancer management costs. Over the years, despite the use of aggressive therapies, the mortality rate remains high; therefore further studies are needed to develop new approaches to cancer management<sup>7,8</sup>. Imaging technologies are the first step in the diagnostic of this disease to decrease mortality. Medical imaging brings many advantages including real time monitoring, without tissue destruction and minimal-invasive procedure<sup>7</sup>. Literature review showed that imaging through screening and symptomatic disease management plays an important role in cancer management (Figure 1). Mammography and

ultrasonography of the breast are used as routine imaging technologies in detection of breast cancer throughout the world.

One of the imaging techniques using in the management of breast cancer is mammography. Mammography, the standard method of breast cancer screening, has the ability to detect breast cancer in early stage<sup>2</sup>. However, the sensitivity of this imaging technique is low in cases with high breast tissue density<sup>10</sup>. Increased breast tissue density in mammography is one of the causes of false negative in mammography due to various causes such as fibrocystic changes<sup>11</sup>. Due to the increase in false-negative mammograms in patients with dense breast tissue, it is recommended that additional screening methods be used to screen these patients. Ultrasound is an ideal complementary method, because of its availability and cheapness. Breast tissue is usually denser in younger women<sup>12</sup>. This dense texture in mammography often appears as a solid white area so it will be difficult to see. In these cases, the use of ultrasound will be an appropriate method to better viewing of the desired tissue<sup>13</sup>. A study in 2008 reported that adding a screening ultrasound to mammography will yield an additional 1.1 to 7.2 cancers per 1000 high-risk women, but it will also substantially increase the number of false positives<sup>14</sup>.

We performed the literature review within the PubMed database using the keywords: "breast, cancer, mammography, ultrasound, with dates from 2000 to 2019. This paper begins by describing commonly used breast cancer detection techniques such as mammography and ultrasonography. We then provide an overview on the performance of combined screening method to early breast cancer detection.

**Mammography:** The goal of breast mammography is to detect cancer earlier, when the treat is more likely.

Mammography screening uses X-ray imaging to find breast cancer before a lump can be felt.<sup>[15]</sup> Mammography has not enough sensitivity in imaging young compact breasts because the encompassing fibro glandular tissue decreases the manifestation of lesions.<sup>[7]</sup> Full field digital mammography is one of the helpful digital imaging systems that offer several privileges over film-based techniques for breast screening. These include lower dose, improved sensitivity for dense breasts, increased dynamic range, computer-aided detection/diagnosis, softcopy review, digital archiving, telemedicine, tomosynthesis, 3-D visualization techniques and reduction in breast compression pressure<sup>9</sup>. Overlapping and obscuring malignancies by normal structures like glandular tissue in the breast, particularly those placed deep in the breast is a potential constraint of 2D mammograms<sup>7</sup>. This can result in cancers being skipped in the scan. Combining tomosynthesis with digital mammography can result in lower false negatives and increase true positives<sup>16</sup>. The use of 3D X-ray systems with tomosynthesis can reduce breast compression<sup>9</sup>. Contrast-enhanced mammography, is an investigational technique that uses iodinated contrast agents. This investigational technique is based on the principle that quick growth of tumors requires enhanced blood reserve through angiogenesis. If the compression device is not activated, contrast needs to be administered. Angiogenesis regions will cause an accumulation of the contrast agent<sup>17</sup>. Tomosynthesis combined with contrast-enhanced mammography is an imaging contrast distribution technique in breast tissue. Therefore, may offer advantages in detecting primary and secondary lesions as well as the possibility to monitor therapy<sup>17,18</sup>. Dual energy contrast mammography could improve detectability of breast lesions at lower radiation doses than non-contrast enhanced mammography but it is needed to be evaluated versus contrast enhanced MRI<sup>19</sup>. This technique has some advantages such as remove the structural noise, and contrast media, then enhance the region surrounding the tumor and increase the detectability of the lesions<sup>20</sup>. Computer-aided detection (CAD) is used to enhance lesion detection efficiency especially in locations where obtaining a second reading is difficult<sup>21</sup>. CAD has an advantage in identifying microcalcifications but less so for breast masses. The CAD has great sensitivity for breast cancer detection on initially and short-term follow-up digital mammograms. Reproducibility for true positive CAD marks is significantly higher than for false positive CAD marks<sup>22</sup>.

Despite the advantages mentioned for mammography imaging methods, the results of various studies are inconsistent. A mega-scale study composed of 231,221 mammograms have indicated that CAD enhances the efficiency of a single reader, yielding increased sensitivity just with a little increment in recall rate<sup>23</sup>. In a study aimed screening for breast cancer with mammography, eight trials included 600,000 women in the analyses in the age range 39 to 74 years were investigated.<sup>[15]</sup> Results of this study showed that three trials did not show a statistically significant reduction in breast cancer mortality at 13 years; four trials showed a significant reduction in breast cancer mortality. Above results showed that breast cancer mortality was an unreliable outcome that was biased in favor of screening, mainly because of differential misclassification of cause of death. The trials with adequate

randomization did not find an effect of screening on total cancer mortality<sup>15</sup>.

**Ultrasonography combined with mammography:** Ultrasonography can investigate the orientation, morphology, internal structure and margins of lesions from multiple planes with high resolution both in predominantly fatty breasts and dense<sup>24</sup>. Some of the ultrasound techniques are the ultrasound elastography, contrast-enhanced ultrasound, 3-D ultrasound, computer-aided detection of breast cancer, and automatic breast-volume scanning. Elastic Sonography is a routine tool in ultrasonic detect which have different types and in general this technique could measure the consistency or hardness of the tissues non-invasively in order to differentiate benign from malignant breast lesions<sup>25</sup>. Contrast-enhanced ultrasound is used in clinical research to reveal the vascular structure, which is useful for differentiative between benign and malignant lesions and follow-up after local treatment<sup>26</sup>. This technique uses intravenously injected gas microbubbles to improve backscattering from the vasculature<sup>27</sup>. 3D ultrasound which allows the calculation of the volume can provide new perspectives in the field of breast ultrasonography<sup>28,29</sup>. Computer-aided diagnosis is used in order to help readers in breast cancer detection and classification. It consists of four stages including preprocessing, segmentation, feature extraction and selection, and classification that may be used as a second reader to improve the radiologists' accuracy in distinguishing malignant from benign lesions<sup>30</sup>.

Review of the literature showed that mammography is not a perfect method to diagnose breast cancer and misses some cases, particularly in women who have dense breasts. Since the ultrasonography can differentiate between cysts and solid tumors, it is used commonly as a diagnostic method to distinguish benign from malignant lesions, therefore, decreases the number of indeterminate mammographically findings. Although some researchers believed that the addition of ultrasonography method will detect those cases that are missed by mammography, others believed that this will increase the false positive tumors and therefore increase the number of biopsies and unnecessary treatment. Ultrasonography is not recommended for screening of breast at average risk for breast cancer<sup>31</sup>. Clinical advices specify ultrasonography as a supplementary checkup for further clarification of ambiguous findings<sup>32</sup>. The guidelines on breast cancer screening specify that ultrasonography should be carried out in the presence of a discrete clinical mass even if negative on mammography<sup>31</sup>. A review of ultrasonography showed the increased biopsy rate in women at average risk, finding a mean positive predictive value of 15%, that is, the percentage of positively classified findings for which no carcinoma was subsequently found ranged from 72% to 98%<sup>33</sup>. Berg (2008) showed an increase in diagnostic accuracy when using ultrasonography in addition to mammography (accuracy of 0.78 for mammography alone compared with 0.91 when mammography is combined with ultrasonography<sup>14</sup>).

A study aimed at compare mammography and ultrasonography findings with those of pathology in patients with breast cancer reported that mammography is the preferred modality in screening breast cancer. Although the use of complementary modality such as ultrasonography,

especially in high-risk women is recommended<sup>34</sup>. In this study the mammography results were positive and false negative in 98.7% and 1.3% of the cases, respectively. Also, the results of ultrasonography in 97.5% and 2.5% of the patients were positive and false negative, respectively. In 2008 a study was performed with this hypothesis that screening ultrasound may demonstrate small, node-negative breast cancers not seen on mammography<sup>14</sup>. Overall the results of that study showed that, adding a single screening ultrasonography to mammography will yield an additional 1.1 to 7.2 cancers per 1000 high-risk case, but it will also substantially increase the number of false positives. In 2018 a study was performed to assess the validity of clinical diagnosis, mammography and breast ultrasonography for accurate detection of the disease. In conclusion, that study showed that clinical diagnosis, ultrasound and mammography can potentially predict breast cancer disease with considerable sensitivity and specificity<sup>35</sup>. Devolli-Disha et al., (2009) examined 546 patients with breast symptoms, by mammography and ultrasonography. Their data indicate that sensitivity and specificity of ultrasonography was statistically significantly greater than mammography in patients with breast symptoms for the diagnosis of breast cancer<sup>11</sup>. However, the sensitivity and specificity of mammography and ultrasonography are varying across different literature (Table 1).

Some studies recommend the use of combination methods for early detection of breast cancer. Kuhl et al., (2005) stated that mammography alone, and also mammography combined with breast ultrasound, seems insufficient for early detection of breast cancer in women who are at increased familial risk. If MRI is used for surveillance, detection of intraductal and invasive familial or hereditary cancer is achieved with a significantly higher sensitivity and at a more favorable stage<sup>44</sup>. Another study reported that after breast conservation therapy in women 50 years or younger, the addition of MRI to annual mammography screening improves diagnosis of early-stage<sup>10</sup>. Nothacker et al., (2009) in a systematic review in order to estimate the risks and benefits of supplemental breast ultrasonography in women with negative mammographic screening with dense breast stated that supplemental ultrasound after negative mammography screening allowed detection of primarily invasive carcinomas in 0.32% of cases in breast density categories 2-4 of the American College of Radiology<sup>49</sup>. They concluded that the reviewed studies showed limited documents that an additional ultrasound examination following a negative mammographic screening be useful for the diagnosis of primarily invasive cancers in cases with dense breast tissue. Therefore, some of prospective validation examinations of supplemental breast ultrasound screening in women with dense breast tissue are needed. These examinations should state the positive predictive value, as well as the specificity, sensitivity and negative predictive value for breast ultrasound.

## CONCLUSION

Mammography is the standard method to screening of breast cancer. Screening using mammography alone will miss some of malignancies, as documented by

retrospective reviews of mammograms after a subsequent screening. In cases where breast tissue density is high in mammography, it is advisable to evaluate patients with other imaging modalities, such as ultrasound. Ultrasonography is a supplemental screening method for mammography that might be able to diagnosis cancer lesions that are not detectable in breast mammography screening. In patient with high risk for breast cancer, adjunct screening can improve the diagnostic yield of breast cancer

## REFERENCES

1. Bray F, Ferlay J, Soerjomataram I, Siegel RL, Torre LA, Jemal A. Global cancer statistics 2018: GLOBOCAN estimates of incidence and mortality worldwide for 36 cancers in 185 countries. *CA: Cancer J Clin.* 2018;68(6):394-424.
2. Sood R, Rositch AF, Shakoor D, Ambinder E, Pool K-L, Pollack E, et al. Ultrasound for Breast Cancer Detection Globally: A Systematic Review and Meta-Analysis. *J. Glob. Oncol.* 2019; 5:1-17.
3. Radmard AR. Five common cancers in Iran. *Arch. Iran. Med.* 2010 Mar 1; 13(2):143.
4. Allahverdipour H, Asghari-Jafarabadi M, Emami A. Breast cancer risk perception, benefits of and barriers to mammography adherence among a group of Iranian women. *Women's health.* 2011;51(3):204-19.
5. Mousavi SM, Montazeri A, Mohagheghi MA, Jarrahi AM, Harirchi I, Najafi M, et al. Breast cancer in Iran: an epidemiological review. *Breast J.* 2007;13(4):383-91.
6. Korolitchouk V, Stanley K, Stjernsward J. The control of breast cancer a World Health Organization perspective. *Cancer.* 1990;65(12):2803-10.
7. Lima ZS, Ebadi MR, Amjad G, Younesi L. Application of Imaging Technologies in Breast Cancer Detection: A Review Article. *Macedo. J. Med. Sci.* 2019;7(5):838.
8. Forootan M, Tabatabaeefar M, Mosaffa N, Ashkalak HR, Darvishi M. Investigating Esophageal Stent-Placement Outcomes in Patients with Inoperable Non-Cervical Esophageal Cancer. *J. Cancer.* 2018;9(1):213-8.
9. Fass L. Imaging and cancer: a review. *Mol. Oncol.* 2008;2(2):115-52.
10. Cho N, Han W, Han B-K, Bae MS, Ko ES, Nam SJ, et al. Breast cancer screening with mammography plus ultrasonography or magnetic resonance imaging in women 50 years or younger at diagnosis and treated with breast conservation therapy. *JAMA Oncol.* 2017;3(11):1495-502.
11. Devolli-Disha E, Manxhuka-Kërliu S, Ymeri H, Kutllovci A. Comparative accuracy of mammography and ultrasound in women with breast symptoms according to age and breast density. *Bosnian J. Basic Med.* 2009;9(2):131.
12. Nandan F, Alladin B. The Role of Ultrasound as a Diagnostic Tool for Breast Cancer in the Screening of Younger Women. *J. Med. Diag. Method.* 2018.
13. Oluwatosin OA, Oladepo O. Knowledge of breast cancer and its early detection measures among rural women in Akinyele Local Government Area, Ibadan, Nigeria. *BMC cancer.* 2006;6(1):271.
14. Berg WA, Blume JD, Cormack JB, Mendelson EB, Lehrer D, Böhm-Vélez M, et al. Combined screening with ultrasound and mammography vs mammography alone in women at elevated risk of breast cancer. *Jama.* 2008;299(18):2151-63.
15. Gøtzsche PC, Jørgensen KJ. Screening for breast cancer with mammography. *Cochrane database of systematic reviews.* 2013(6).
16. Bohndiek SE, Cook EJ, Arvanitis CD, Olivo A, Royle GJ, Clark AT, et al. A CMOS active pixel sensor system for laboratory-based x-ray diffraction studies of biological tissue. *Phys. Med. Biol.* 2008;53(3):655.

17. Jong RA, Yaffe MJ, Skarpathiotakis M, Shumak RS, Danjoux NM, Guneseckara A, et al. Contrast-enhanced digital mammography: initial clinical experience. *Radiol.* 2003;228(3):842-50.
18. Diekmann F, Bick U. Tomosynthesis and contrast-enhanced digital mammography: recent advances in digital mammography. *Eur. Radiol.* 2007;17(12):3086-92.
19. Flynn MJ, editor *Medical Imaging 2005: Physics of Medical Imaging*. Medical Imaging 2005: Phys. Med. Imaging.; 2005.
20. Lewin JM, Isaacs PK, Vance V, Larke FJ. Dual-energy contrast-enhanced digital subtraction mammography: feasibility. *Radiol.* 2003;229(1):261-8.
21. Campadelli P, Casiraghi E, Artioli D. A fully automated method for lung nodule detection from postero-anterior chest radiographs. *IEEE Trans. Med. Imaging.* 2006;25(12):1588.
22. Kim SJ, Moon WK, Cho N, Cha JH, Kim SM, Im J-G. Computer-aided detection in full-field digital mammography: sensitivity and reproducibility in serial examinations. *Radiol.* 2008;246(1):71-80.
23. Gromet M. Comparison of computer-aided detection to double reading of screening mammograms: review of 231,221 mammograms. *Am. J. Roentgenol.* 2008;190(4):854.
24. Guo R, Lu G, Qin B, Fei B. Ultrasound imaging technologies for breast cancer detection and management: A review. *Ultrasound Med. Biol.* 2018;44(1):37-70.
25. Bamber J, Cosgrove D, Dietrich C, Fromageau J, Bojunga J, Calliada F, et al. EFSUMB guidelines and recommendations on the clinical use of ultrasound elastography. Part 1: Basic principles and technology. *Eur. J. Ultrasound.* 2013;34(02):169-84.
26. Kim E-A, Yoon K-H, Lee YH, Kim HW, Juhng SK, Won JJ. Focal hepatic lesions: contrast-enhancement patterns at pulse-inversion harmonic US using a microbubble contrast agent. *Korean J. Radiol.* 2003;4(4):224-33.
27. Calliada F, Campani R, Bottinelli O, Bozzini A, Sommaruga MG. Ultrasound contrast agents: basic principles. *Eur. J. Radiol.* 1998;27: S157-S60.
28. Jia W-R, Chai W-M, Tang L, Wang Y, Fei X-C, Han B-S, et al. Three-dimensional contrast enhanced ultrasound score and dynamic contrast-enhanced magnetic resonance imaging score in evaluating breast tumor angiogenesis: correlation with biological factors. *Eur. J. Radiol.* 2014;83(7):1098-105.
29. Sridharan A, Eisenbrey JR, Machado P, Ojeda-Fournier H, Wilkes A, Sevrukov A, et al. Quantitative analysis of vascular heterogeneity in breast lesions using contrast-enhanced 3-D harmonic and subharmonic ultrasound imaging. *IEEE Trans. Ultrasonics, ferroelectrics, and frequency control.* 2015;62(3):502-10.
30. Cheng H-D, Shan J, Ju W, Guo Y, Zhang L. Automated breast cancer detection and classification using ultrasound images: A survey. *Pattern recognition.* 2010;43(1):299-317.
31. Gartlehner G, Thaler K, Chapman A, Kaminski-Hartenthaler A, Berzaczy D, Van Noord MG, et al. Mammography in combination with breast ultrasonography versus mammography for breast cancer screening in women at average risk. *Cochrane Database of Systematic Reviews.* 2013(4).
32. Albert U-S, Altland H, Duda V, Engel J, Geraedts M, Heywang-Köbrunner S, et al. 2008 update of the guideline: early detection of breast cancer in Germany. *J. Cancer Res. Clin. Oncol.* 2009;135(3):339-54.
33. Nothacker M, Duda V, Hahn M, Warm M, Degenhardt F, Madjar H, et al. Early detection of breast cancer: benefits and risks of supplemental breast ultrasound in asymptomatic women with mammographically dense breast tissue. A systematic review. *BMC cancer.* 2009;9(1):335.
34. Haghighi F, Naseh G, Mohammadifard M, Abdollahi N. Comparison of mammography and ultrasonography findings with pathology results in patients with breast cancer in Birjand, Iran. *Electron. Physician.* 2017;9(10):5494.
35. Badu-Peprah A, Adu-Sarkodie Y. Accuracy of clinical diagnosis, mammography and ultrasonography in preoperative assessment of breast cancer. *Ghana Med. J.* 2018;52(4):235-41.
36. Omidiji OA, Campbell PC, Iurhe NK, Atalabi OM, Toyobo OO. Breast cancer screening in a resource poor country: Ultrasound versus mammography. *Ghana Med. J.* 2017;51(1):6-12.
37. Berg WA, Bandos AI, Mendelson EB, Lehrer D, Jong RA, Pisano ED. Ultrasound as the primary screening test for breast cancer: analysis from ACRIN 6666. *J. Natl. Cancer Inst.* 2016;108(4): djv367.
38. Shen S, Zhou Y, Xu Y, Zhang B, Duan X, Huang R, et al. A multi-centre randomised trial comparing ultrasound vs mammography for screening breast cancer in high-risk Chinese women. *Br. J. Cancer.* 2015;112(6):998-1004.
39. Tan K, Mohamad ZA, Rumaisa M, Siti MAM, Radhika S, Nurismah M, et al. The comparative accuracy of ultrasound and mammography in the detection of breast cancer. *Med. J. Malaysia.* 2014;69(2):79-85.
40. Shao H, Li B, Zhang X, Xiong Z, Liu Y, Tang G. Comparison of the diagnostic efficiency for breast cancer in Chinese women using mammography, ultrasound, MRI, and different combinations of these imaging modalities. *J. X-Ray Sci. Technol.* 2013;21(2):283-92.
41. Lehman CD, Lee CI, Loving VA, Portillo MS, Peacock S, DeMartini WB. Accuracy and value of breast ultrasound for primary imaging evaluation of symptomatic women 30-39 years of age. *Am. J. Roentgenol.* 2012;199(5):1169-77.
42. Uchida K, Yamashita A, Kawase K, Kamiya K. Screening ultrasonography revealed 15% of mammographically occult breast cancers. *Breast Cancer.* 2008;15(2):165-8.
43. Lehman CD, Isaacs C, Schnall MD, Pisano ED, Ascher SM, Weatherall PT, et al. Cancer yield of mammography, MR, and US in high-risk women: prospective multi-institution breast cancer screening study. *Radiol.* 2007;244(2):381-8.
44. Kuhl CK, Schrading S, Leutner CC, Morakkabati-Spitz N, Wardelmann E, Fimmers R, et al. Mammography, breast ultrasound, and magnetic resonance imaging for surveillance of women at high familial risk for breast cancer. *J. Clin. Oncol.* 2005;23(33):8469-76.
45. Sim L, Hendriks J, Fook-Chong S. Breast ultrasound in women with familial risk of breast cancer. *Ann. Acad. Med. Singapore.* 2004;33(5):600-6.
46. Hata T, Takahashi H, Watanabe K, Takahashi M, Taguchi K, Itoh T, et al. Magnetic resonance imaging for preoperative evaluation of breast cancer: a comparative study with mammography and ultrasonography. *J. Am. Coll. Surg.* 2004;198(2):190-7.
47. Kriege M, Brekelmans CT, Boetes C, Besnard PE, Zonderland HM, Obdeijn IM, et al. Efficacy of MRI and mammography for breast-cancer screening in women with a familial or genetic predisposition. *N. Engl. J. Med.* 2004;351(5):427-37.
48. Houssami N, Irwig L, Simpson JM, McKessar M, Blome S, Noakes J. Sydney Breast Imaging Accuracy Study: comparative sensitivity and specificity of mammography and sonography in young women with symptoms. *Am. J. Roentgenol.* 2003;180(4):935-40.
49. Nothacker M, Duda V, Hahn M, Warm M, Degenhardt F, Madjar H, et al. Early detection of breast cancer: benefits and risks of supplemental breast ultrasound in asymptomatic women with mammographically dense breast tissue. A systematic review. *BMC cancer.* 2009;9(1):335.

Figure 1: The role of imaging in cancer management (9)

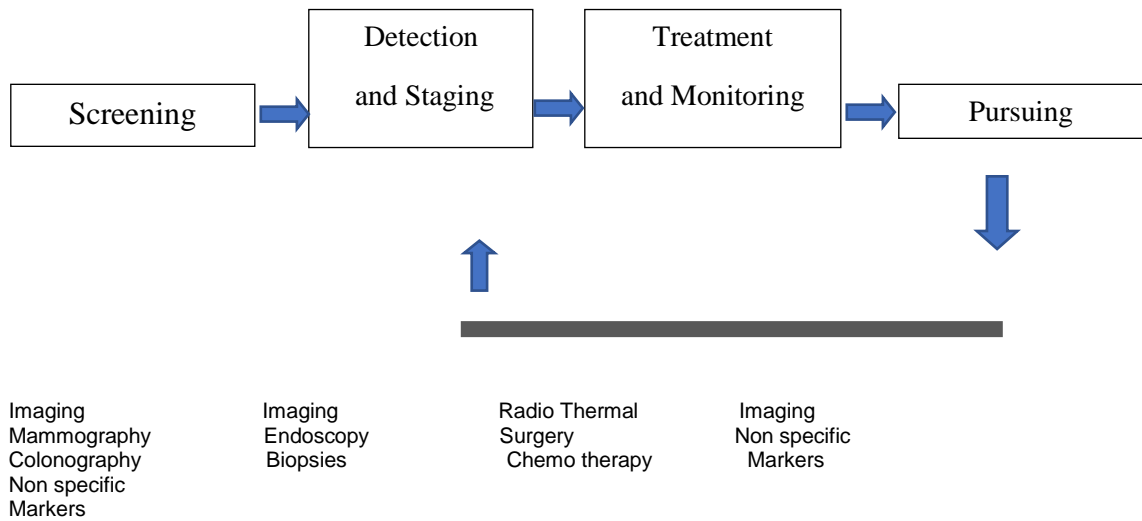


Table 1. Comparative studies for sensitivity and specificity values of mammography and ultrasonography (95% CI)

First author, year (ref.)	Mammography		Ultrasonography	
	Sensitivity (%)	Specificity (%)	Sensitivity (%)	Specificity (%)
Omidiji, 2017 (36)	86	56	89	22
Berg, 2016 (37)	53	90	52	86
Shen, 2015 (38)	57	100	94	100
Tan, 2014 (39)	49	89	82	84
Shao, 2013 (40)	73	63	80	60
Lehman, 2012 (41)	61	94	96	89
Devolli-Disha, 2009 (11)	52	74	73	89
Uchida, 2008 (42)	84	99	75	97
Lehman, 2007 (43)	33	75	17	63
Kuhl, 2005 (44)	33	97	40	90
Sim, 2004 (45)	54	85	83	64
Hata, 2004 (46)	22	86	21	85
Kriege, 2004 (47)	33	95	-	-
Houssami, 2003 (48)	76	88	82	88
Total	55	86	74	79