

Frequency of Aspergillus Infection with Nasal Polyps and Proptosis

BAKHT AZIZ¹, AMER AYUB AWAN², SAMIA ANDLEEB³, MUHAMMAD DAWOOD SALEEM⁴

ABSTRACT

Aim: To determine the frequency of aspergillus infection in patients with nasal polyps and proptosis.

Study design: Cross sectional survey

Setting of study: Department of ENT, Ameer-ud-din Medical College/PGMI/LGH, Lahore

Duration : six months (March 2017 to August 2017)

Sample size: 70 patients

Methods: Non probability purposive sampling. All the 70 patients with nasal polyps and proptosis that were included in this study were assessed by clinical examination. They were investigated specifically by computed tomographic scan to see the intraorbital extension of the disease and fungal culture of the tissue after surgery to determine the presence or absence of aspergillus infection. Culture reports were collected within seven days following surgery in the indoor department of ENT. Informed consent for surgery was taken. Demographic profile and relevant data was recorded on research tools. Data was entered and analyzed with SPSS version 17. Quantitative variable like age was presented by calculating mean and standard deviation. Qualitative variables like gender and presence or absence of aspergillus were presented by calculating frequencies and percentages.

Results: Male and female proportion was almost equal with slight female predominance, 46% and 54% respectively. Mean age was 26.11 with S.D±10.32. On In 45 (64.3%) patients, Aspergillus species were demonstrated on fungal culture and rest were negative.

Conclusion: Aspergillus species was found in approximately two third of patients 45(64.3%) out of 70 patients with nasal polyps and proptosis. So a strong clinical diagnosis of aspergillus rhinosinusitis can be made in patients presenting with nasal polyps with proptosis.

Keywords: Nasal polyp, proptosis, aspergillus infection

INTRODUCTION

Different species of fungi are found to involve nose and paranasal sinuses, the most common being the aspergillus, mucormycosis and rhizopus. There are more than 185 species of aspergillus and over 95% of all infections are caused by aspergillus fumigatus, aspergillus flavus and aspergillus niger¹. Aspergillus accounts for 6-8% of patients with chronic rhinosinusitis (CRS)^{2,3}. Fungal rhinosinusitis (FRS) may present with nasal polyps, nasal obstruction, nasal discharge, post nasal drip, anosmia and proptosis⁴. Nasal polyps are non-neoplastic masses of edematous and pendunculated sinonasal mucosa. Multiple ethmoidal polyps can occur with invasive (acute fulminant or chronic indolent or granulomatous fungal rhino sinusitis) and non invasive (fungal ball or allergic fungal rhinosinusitis) variety⁵. The morbidity associated with nasal polyps depends upon its size. Small polyps may not produce any symptom while large polyps can cause nasal obstruction, nasal discharge, post nasal drip and rhinorrhea. Massive

polyps can alter craniofacial structures leading to proptosis, diplopia and hypertelorism⁶. Proptosis is the forward displacement of the eyeball in the orbit. Proptosis is the most frequent morbidity associated with extensive sinonasal polyps. It is caused by bone expansion or bone erosion of paranasal sinuses due to pressure effect or fungal invasion. This usually damages the lamina papyracea which is a paper thin bone of the ethmoid forming the medial wall of the orbit⁷. Paranasal sinuses are situated in close proximity to the orbit and the cranial cavity. So infection of sinuses may spread to involve these areas leading to a variety of complications ranging from pre-septal cellulitis to orbital abscess. Catastrophic results of nasal polyps with proptosis can result in blindness as well. Pre requisites for diagnosis of fungal rhinosinusitis are sinonasal polyps, infiltrative or non infiltrative fungal hyphae on histopathological examination of the resected polyps and positive fungal culture of the tissue following surgery⁸. Nasal polyps should be diagnosed early and treated aggressively as the larger ones increase the chances of craniofacial deformities and morbidities associated with nasal polyps. A ten years retrospective analysis of fungal rhinosinusitis by Lwen PC showed aspergillus present in most patients

^{1,4}Assistant Professor, ENT, ²Senior Registrar, ENT, ³MO, ENT, Ameer-ud-din Medical College/ Post Graduate Medical Institute/ Lahore General Hospital, Lahore
Correspondence to Dr Bakht Aziz, Email: bakhtaziz@gmail.com
Cell:0300-9450311

who had associated proptosis⁹. Jerome in 2006 also reported a 35 years retrospective study with similar results¹⁰. In another study conducted by Khan et al the fungal culture revealed septate hyphae with dichotomous acute angle branching suggestive of aspergillus in 10 out of 12 patients¹². A part from background of fungal rhinosinusitis, there are certain deficiency in current pool of knowledge like the association of nasal polyps having proptosis with the aspergillus infection. Close association of nasal polyps with proptosis and aspergillus are still matters under debate. Several authors have proposed their own recommendations but much research is still needed to cope with these deficiencies. Our research work had the same objectives. The frequency of aspergillus infection in cases of nasal polyps with proptosis has a rationale of preventing orbital complications of the disease like ophthalmoplegia and blindness. Early diagnosis can help in better management and preventing morbidities in the form of blindness.

The objective of the study was to determine the frequency of aspergillus infection in patients with nasal polyps and proptosis.

OPERATIONAL DEFINITION

Aspergillus: sinonasal aspergillus presents with nasal polyps, nasal obstruction, nasal discharge and proptosis. It is diagnosed by culture of the tissue following surgery.

Nasal polyps: nasal polyps are non neoplastic masses of edematous and penduculate sino nasal mucosa. They are diagnosed by clinical examination

Proptosis: proptosis is the forward displacement of the eyeball in the orbit. It was assessed by computed tomographic scans.

MATERIAL AND METHOD

This cross sectional survey was conducted in the Department of ENT, Ameer-ud-din Medical College/ Post Graduate Medical Institute/ Lahore General Hospital, Lahore. The duration of the study was six months from March 2017 to August 2017. Sample size was 70 patients. Non probability purposive sampling technique was used.

Inclusion criteria: patients coming with nasal polyps and proptosis after clinical examination and computed tomographic scans showing intra orbital extension of polyps causing proptosis.

Exclusion criteria: patients coming with proptosis due to orbital lesions and other nasal masses causing proptosis like antrochonal polyp, nasal carcinoma, inverted papiloma and angiofibroma diagnosed on clinical examination and computed tomographic scans were excluded from the study.

Data collection procedure: All 70 patients with nasal polyps and proptosis included in this study were assessed by clinical examination. They were

investigated specifically by computed tomographic scan to see the intra orbital extension of the disease and fungal culture of the tissue was sent following surgery, to see the presence of aspergillus infection. Culture reports were collected within seven days following the surgery in the indoor department of ENT. Informed consent for surgery was taken from the patient after being briefed about the procedure. The demographic profile and relevant data was recorded.

Data analysis: The data was entered and analyzed on SPSS version 10, a computer based software programme. Quantitative variables like age were presented by calculating mean and standard deviation. Qualitative variables like gender and presence or absence of aspergillus were presented by calculating frequencies and percentages.

RESULTS

Male and female proportion was almost equal with slight female predominance, 46% and 54% respectively. Mean age was 26.11 with S.D±10.32. On In 45(64.3%) patients, Apeargillus species were demonstrated on fungal culture and rest were negative.

Graph 1: Gender

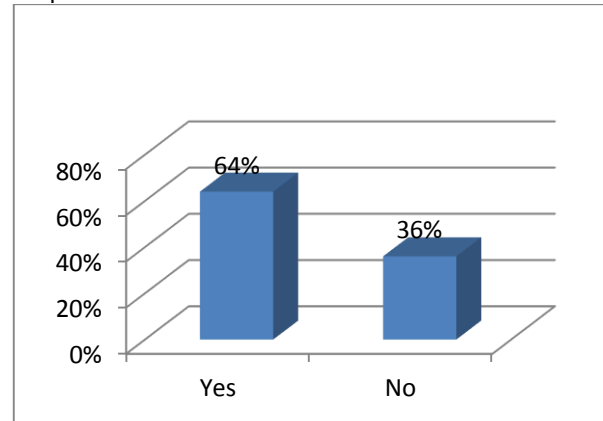


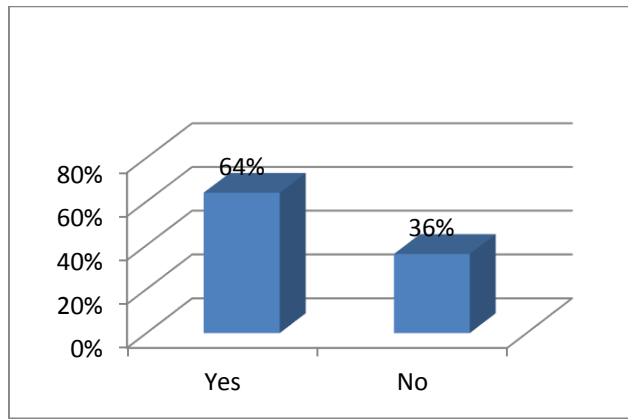
Table 1: Age in years (n=70)

Mean	26.11
SD	10.32
Range	45
Minimum	10
Maximum	55

Table 2: Frequency distribution of presence or absence of aspergillus infection(n=70)

Aspergillus Infection	Frequency	%age	Cumulative%
Yes	45	64.3	64.3
No	25	35.7	100

Graph 2: Frequency distribution of Aspergillus infection (presence or absence)



DISCUSSION

There are more than 400,000 fungal species and approximately 400 are human pathogens. Different species of fungi are found to involve nose and paranasal sinuses, the more common being aspergillus, mucormycosis and rhizopus. Over 95% of all infections are caused by aspergillus^{2,11}. Sinonasal aspergillus may present with nasal polyps and proptosis^{3,4}. Proptosis is the forward displacement of the eyeball in the orbit. It is caused by bone expansion or bone erosion of the paranasal sinuses due to fungal invasion³. Orbital involvement which usually occurs by contiguous spread of the paranasal sinuses is considered to worsen the prognosis of sinonasal aspergillous. So it should be diagnosed early and treated aggressively to decrease the chance of craniofacial deformities and morbidities^{7,12}. Tremendous work has been done internationally and a lot of published material is available on sinonasal pathologies associated with fungus but still our literature is scanty on this subject and lot of research work is needed in this regard¹. Average age of patients in our study was 26.11±10.32 and they ranged in age from 10 to 55 years. Our findings stimulate in this regard with the local researchers. The average mean age in the study of Mian et al was 24 years, while Iqbal et al found it to be 18 years^{13,14}. There were 32(45.7%) male and 38(54.3%) female patients in our study. While gender distribution was 1:1.88. Gender distribution in our study is similar to a foreign study by Singh N and Bholodia NH in this regard¹⁵. Resected polyps obtained following surgery was inoculated on Saboraud Dextrose Agar with Chloramphenicol and incubated at 37 and 25 centigrade for 3 to 10 days and were examined for presence or absence of the Aspergillus infection. Our study showed 45(64.3%) patients positive for aspergillus infection out of 70 patients. Positive aspergillus culture was reported in almost two third of our cases. This result is in accordance with the local studies conducted by Rehman et al¹⁶. In another study conducted by Khan et al the fungal culture

revealed septate hyphae with dichotomous acute angle branching suggestive of aspergillus in 10 out of 12 patients¹². It is strongly recommended that every case of nasal polyps with proptosis should be thoroughly scrutinized with detail history, clinical examination and specific investigations like computed tomographic scans. Tissue removed following surgery should always be subjected to culture to identify the presence or absence of aspergillus infection. These efforts can change the whole line of management both in terms of surgical technique and medical therapy to reduce fatal complication like blindness associated with the disease.

CONCLUSION

Aspergillus specie was found in approximately two third of patients 45(64.3%) out of 70 patients with nasal polyps and proptosis. So a strong clinical diagnosis of aspergillus rhinosinusitis can be made in patients presenting with nasal polyps with proptosis.

REFERENCES

1. Thahim K, Javaid MA, Marfani MS. Presentation and management of allergic fungal rhinosinusitis. *J Col Phys Surg Pak* 2007;17:23-7.
2. Shah PD, Deokule JS. Isolation of aspergillus nidulans from a case of fungal rhinosinusitis- a case report. *Indian J Pathol Microbiol* 2007; 50:677-8.
3. Barclay L, Lie D. Diagnosis of allergic fungal rhinosinusitis clarified. *Arch Otolaryngol Head Neck Surg* 2006;132:173-8.
4. Agarwal S, Kanga A, Sherma V. Invasive aspergillois involving multiple paranasal sinuses-a case report. *Indian J Microbiol* 2005; 23:195-7.
5. Andrew AE, Bryson JM, Row-Jones JM. Site of origin of nasal polyps: relevance to pathogenesis and management. *Rhinology* 2005; 43(3):180-4.
6. Pavliczak R, Levandowsk et al. Pathogenesis of nasal polyps: an update. *Curr Allergy Asthma Rep* 2005; 5(6): 463-71.
7. Haq A, Abbas S, Ayub MW. Advanced proptosis and hypertelorism- a complication of fungal sinusitis and extensive polyposis. *Pak Armed Forces Med* 2008; 58:11-13.
8. Joshul, Schlf, Ahmad MS. Chronic rhizopus invasive fungal rhinosinusitis in an immunocompetent host. *Laryngoscope* 2004;114: 1533-50.
9. Lwen PC. Invasive mold sinusitis. *Clin Infec Dis* 1997; 24(6): 1178-84.
10. Jerome B. Paranasal fungus. *Am J Surg Path* 2006;30(6): 713-20.
11. Conclaves AB, Paterson RR, Lima N. Survey and significance of filamentous fungi from tap water. *Int J Hyg Environ Health* 2006; 209: 257-64.
12. Khan AR, Ali F et al. Invasive sino-orbital aspergillois in immunocompetent host. *J Med Sci* 2009; 17(2): 87-91.
13. Iqbal K, saqulain G, Jalisi M. Nasal polyposis and fungal sinusitis-efficacy of caldwell luc as a therapeutic procedure. *Pak J Otolaryngol* 1993; 9: 173-6.
14. Mian MY, Kamal SA, Senthikumaran G, et al. Allergic fungal sinusitis: current status. *Pak J Otolaryngol* 2002; 18: 31-40.
15. Singh N, Bholodia NH. Allergic fungal sinusitis- earlier diagnosis and management. *J Laryngol Otol* 2005; 119: 875.
16. Rehman A, Haq I, Qadri SH, et al. Frequency of allergic fungal rhinosinusitis in patients with nasal polyps and associated risk factors. *Pak J Med Health Sci* 2009; 3: 2-10.