

# A Study to Evaluate $\alpha$ -Methylacyl Co-A Racemase Expression in Hyperplasia and Different Grades of Adenocarcinoma of Prostate

TAHIRA TABASSUM\*, AYESHA IMTIAZ, RUKHSANA JABEEN

## ABSTRACT

**Aim:** To evaluate  $\alpha$ -methylacyl Co-A racemase (AMACR) expression pattern in hyperplasia and different grades of adenocarcinoma of prostate.

**Design:** Descriptive study.

**Place:** Post Graduate Medical Institute, Lahore.

**Method:** One hundred biopsies were taken from Lahore General Hospital. After haematoxylin and eosin staining, AMACR immunostaining was done.

**Results:** Total one hundred biopsies (50 cases each of hyperplasia and carcinoma) were included in present study. Age comparison in hyperplasia and carcinoma cases showed statically significant ( $p=0.001$ ) difference. On histological examination, all carcinoma cases were graded using Gleason's Scoring System. None of the cases were well differentiated, 23(46%) were poorly differentiated and 27(54%) showed moderate differentiation. Carcinoma cases mostly presented with high grade cancers. After diagnosing on H&E, all the cases were immunostained with AMACR. All hyperplasia cases showed no reactivity while all carcinoma cases expressed AMACR.

**Conclusion:** It was observed that all cases of hyperplasia were negative whereas all carcinoma cases showed positive AMACR expression. It was concluded that AMACR is a useful immunomarker for diagnosing challenging cases of prostatic adenocarcinoma.

**Key words:** Prostate, Cancer, Hyperplasia, H&E, AMACR, Gleason's scoring

---

## INTRODUCTION

Worldwide adenocarcinoma of prostate is the second most common non-cutaneous malignant tumor in men<sup>1,2</sup>. Its incidence is increasing in Asia, though it is still not high than that seen in western countries<sup>3</sup>.

Digital rectal examination and prostate-specific antigen measurement is carried out for screening purposes. However PSA is not specific to cancer, as it shows positive staining even in benign lesions and results in false diagnosis<sup>4</sup>.

There are certain benign mimickers of prostate cancer and also typical architectural and cytological features are not always seen in small foci of needle biopsies so sometimes diagnosis of prostate cancer becomes a diagnostic challenge<sup>5,6</sup>. Severe adverse consequences can result due to false diagnosis of cancer. Therefore, there is a strong need for a prostate cancer specific tumor marker with high sensitivity and specificity for accurate and prompt diagnosis of prostate cancer<sup>7</sup>.

Various tumor markers are in use for diagnosis of prostatic adenocarcinoma including markers specifically used for basal cells such as 34 $\beta$ E12 and p63<sup>8</sup>. 34 $\beta$ E12 is a high-molecular-weight cytokeratin that yields cytoplasmic staining in basal cells. p63

imparts positive nuclear staining of basal cells in benign prostatic lesions<sup>9</sup>.

However, the use of immunostains used for basal cells is not without pitfalls because there are lesions in which basal cell layer is retained in a patchy fashion such as atypical adenomatous hyperplasia adenosis and atrophy. Basal cells are also retained in high-grade prostatic intraepithelial neoplasia.<sup>10</sup> Furthermore, false-negative basal cell staining may result from prolonged formalin fixation<sup>11</sup>.

A new tumor marker,  $\alpha$ -methylacyl Co-A racemase has been introduced<sup>11</sup> which is highly sensitive to malignant cells of prostate cancer<sup>12</sup>.

Studies from various institutions have shown that AMACR is important marker for the diagnosis of prostatic cancer irrespective of grade of tumor, with 83% to 100% sensitivity and 78% to 99% specificity<sup>13,14,15,16</sup>.

The aim of this study was to determine the role of this novel marker for accurate and prompt diagnosis of prostate carcinoma as the incidence of this cancer is increasing in our part of the world and a large number of elderly male population is affected.

## MATERIALS AND METHODS

This descriptive study was carried out in Pathology department of Postgraduate Medical Institute, Lahore.

---

\*Department of Pathology, Sargodha Medical College, Sargodha  
Department of Pathology, Azra Naheed Medical College, Lahore  
Correspondence to Dr. Tahira Tabassum, 52/3 Civil Lines, Awan Colony, Sargodha, Email: drtahirat@yahoo.com, Cell 03009601602

Specimens were obtained from LGH, Lahore. Sample size was one hundred biopsy specimens

**Acquisition of Biopsy Specimens:** After informed consent, biopsies of sixty cases undergoing various surgical procedures for prostate cancer and benign lesions were received from Urology Ward of LGH, Lahore.

Surgical samples of the following types were taken;

- Radical prostatectomy specimens
- Trans-urethral resection of prostate (TURP) specimens
- Core needle biopsy specimens

All biopsies were collected in 10% formalin.

**Tissue processing and cutting:** For large biopsies i.e. radical prostatectomy and TURP specimens, detailed gross examination was done. Representative sections were taken from intratumoral, paratumoral, marginal and surrounding normal tissue in cases of radical prostatectomy specimens. Small biopsies i.e., core needle biopsy specimens were submitted entirely. All biopsy specimens were subjected to automated tissue processor for various tissue processing steps including dehydration, clearing, paraffin impregnation and embedding. Paraffin embedded blocks were made. Two sections of 4-6  $\mu\text{m}$  thickness for H&E staining and one section of 3-5  $\mu\text{m}$  for AMACR immunostaining were cut from each block with rotary microtome.

**H&E Staining:** From each block 2 sections were stained with H&E using standard method of Harris haematoxylin<sup>17</sup>.

**Morphological Examination:** Microscopic examination of H&E stained slides was performed for the diagnosis of hyperplasia or carcinoma of the prostate and also to assign the histological grades according to Gleason's scoring system.

**AMACR Immunohistochemical Staining:** One 3-5  $\mu\text{m}$  thick section from each block was taken on slides and stained with monoclonal anti-AMACR antibody (mouse AMACR monoclonal antibody by abcam, 2A10F3, IgG2b, peroxisomes by using avidin-biotin-peroxidase method.

**Interpretation of Results:** Cytoplasmic staining was the basis of AMACR expression. The lesion was declared positive when expression was circumferential and stronger than the staining of benign glands in the background. The AMACR positive staining was expressed as strong, moderate or weak. The expression was considered negative when it showed very weak and focal staining or when no cell expresses AMACR at detectable level.

**Statistical Analysis:** Using SPSS version 18, statistical analysis was carried out. All means were described as mean  $\pm$  standard deviation. To compare qualitative data, Pearson Chi Square test was used. For comparison of means with two categories of

study variables, Student's t test was used. A p value of equal to or less than 0.05 was regarded as significant.

## RESULTS

Out of total one hundred cases, 50 cases each of hyperplasia and cancer of prostate were included in this study. The patients with hyperplasia were in the age range from 55 to 80 years and the mean was 63.54 years. Maximum number of cases was in 66-75 years range constituting 66% (Fig. 1). The most common presenting complaint was frequency of urination seen in 31 (62%) cases. Discomfort was found in 16 (32%) patients. Three (6%) cases presented with backache while hematuria was not experienced by any patient (Fig. 3).

Prostate cancer cases presented in the age ranged from 60-85 years, mean was 74.8 years (Fig. 2). Maximum number of cases was over seventy years making 70%. Comparison of age in hyperplasia and cancer is shown in table 1. There was a statistically significant difference ( $p=0.001$ ). The most common presenting feature was discomfort which was experienced by 29 (58%) cases while hematuria occurred in 14 (28%) cases. Backache was experienced by only 2 (4%) patients. Five patients showed frequency (Fig. 3).

All cases of prostate cancer, on microscopic examination of H&E stained slides were graded according to Gleason's scoring system (Table 1). Twenty three (46%) were designated as poorly differentiated (Table 2), 27 (54%) were moderately differentiated and none of the cases were found to be well differentiated (Table 3). It was observed that majority of the cases presented with high grade cancers.

All the 100 cases were stained with AMACR after diagnosing on H&E. It was found that all the 50 cases of cancer showed positive, cytoplasmic, circumferential and granular staining pattern with AMACR whereas none of the hyperplasia cases expressed positive staining.

AMACR expression was also observed in different grades of cancer (Table 3). No correlation was found between different grades of cancer and staining pattern of AMACR as 5 cases with Gleason's score 6(3+3) strongly expressed AMACR, 6 exhibited moderate and two showed weak positive expression while 3 cases with Gleason's score 7(3+4) expressed weak, 4 moderate and 7 expressed strongly. Eight cases with Gleason's score 8(4+4) showed strong, 3 expressed moderate and none of the cases gave weak expression. High grade carcinomas with Gleason's score 9(4+5), 5 showed strong positive, cytoplasmic, granular staining

pattern, 4 gave moderate and 3 had weak expression (Table 3).

Table 1: Age Comparison in Hyperplasia & Carcinoma

Age	Hyperplasia	Carcinoma
<60	16	0
>60	34	50

p value = 0.001

Table 2: Grading of Carcinoma of Prostate

Differentiation	Gleason's score	n	%age
Poor	8 - 10	27	54
Moderate	5 - 7	23	46
Well	2 - 4	00	0

Table 3: Comparison of AMACR Expression and Different Grades of Cancer

n	Gleason's score	AMACR Staining		
		Weak	Moderate	Strong
13	6	2	6	5
14	7	3	4	7
11	8	0	3	8
12	9	3	4	5

Fig. 1: Age groups in hyperplasia

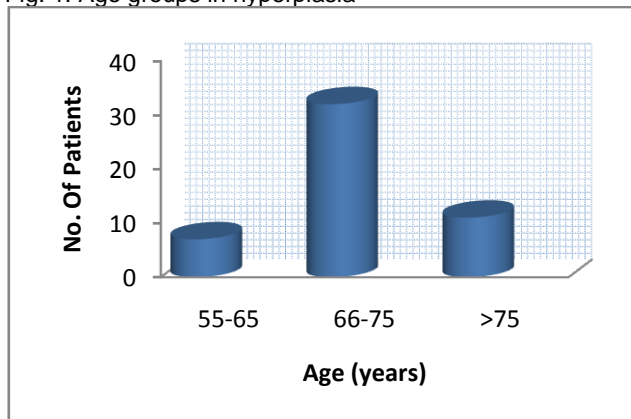


Fig. 2: Age groups in adenocarcinoma

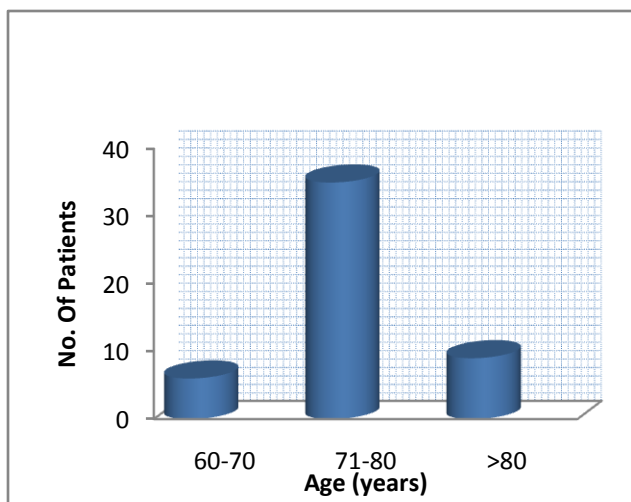
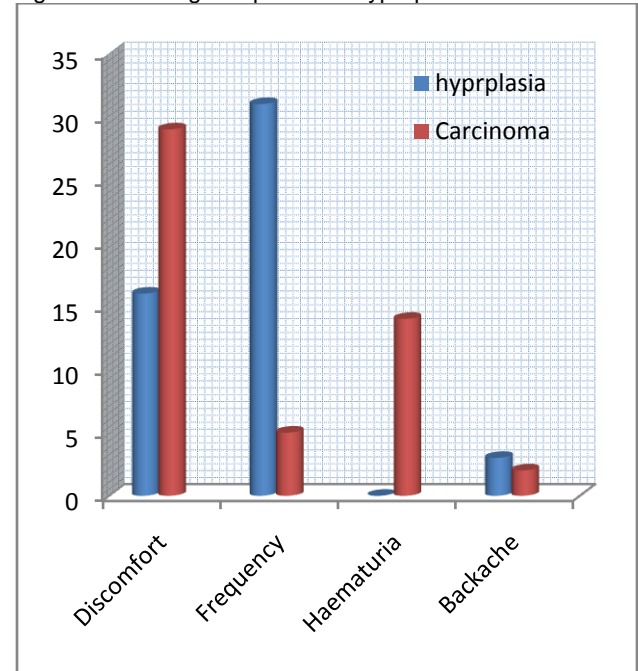


Fig. 3: Presenting complaints in hyperplasia and carcinoma



## DISCUSSION

Our study showed that mean age at presentation of patients with hyperplasia was 63.54 years and the range was from 55 to 80 years. Mostly these patients presented in the age group of 66 to 75 years making 66%(Fig.1). Same results were identified in a study carried out by Mansoor (2003)<sup>18</sup> who found that mean age of the patients of hyperplasia of prostate was 64.3 years.

The most frequent presenting complaint in patients with hyperplasia was frequency of urination which was experienced by 31(62%) cases. Discomfort was seen in 16(76.86%) patients. Three(6%) cases had backache whereas hematuria was not experienced by any patient of hyperplasia(Fig.3). These observations are consistent with the study project conducted by Pervez et al. (2006)<sup>19</sup>.

Patients of prostate cancer presented in the age range of 60 to 85 and the mean was 74.8 years. Most of the patients were more than 70 years of age (Fig.2). These observations are close to the results of the study performed by Sadjadi et al. (2007)<sup>20</sup> who found that the mean age of cancer patients was 67±1years. It was found that patients present late in our region.

In this study, Gleason's scoring of prostate cancer cases revealed that 27(54%) were poorly differentiated, 23(46%) showed moderate differentiation and none of the tumors were well

differentiated (Table 1). These findings are in accordance with the study conducted by Ahmed and Muzaffer (2002).<sup>21</sup>

In the present study, after diagnosing on H&E, all the cases of prostatic hyperplasia and carcinoma were immunostained with AMACR. On microscopic examination of AMACR stained slides, AMACR expression pattern in hyperplasia and cancer was observed. It was found that no positive staining was seen in hyperplasia cases while all the 50 cancer cases expressed positive, circumferential, cytoplasmic, and granular staining which was described as strong, moderate or weak. Our results are consistent with study of Yang (2003)<sup>22</sup> who worked on eighty prostate biopsies. They reported that all malignant cases showed strongly positive expression whereas all benign lesions did not express AMACR.

These results are also consistent with Beach (2002)<sup>16</sup> who conducted a study to see AMACR staining in 366 biopsies. They observed diffuse, intracytoplasmic positive AMACR staining in cases of prostate cancer which was almost never observed in non-cancerous prostate glands<sup>16</sup>.

In addition, in this study, it was observed that there was no correlation between Gleason's score and AMACR expression which was observed in different grades of prostate cancer (Table 3). Out of total 13 cases with Gleason's score 6(3+3), 2 exhibited weak, six moderate and five showed strong positive expression whereas out of 14 cases with 7(3+4) Gleason's score, 3 gave weak, 4 moderate and 7 expressed strong staining. Total cases with Gleason's score 8(4+4) were 11, 8 showed strong, 3 moderate and none showed weak staining. expression, one moderate and 5 gave strong positive staining. Out of total 12 cancers with score 9(4+5), 5 showed strong, 4 moderate and 3 strong staining. Our results are similar to the findings of Shah (2002)<sup>23</sup>.

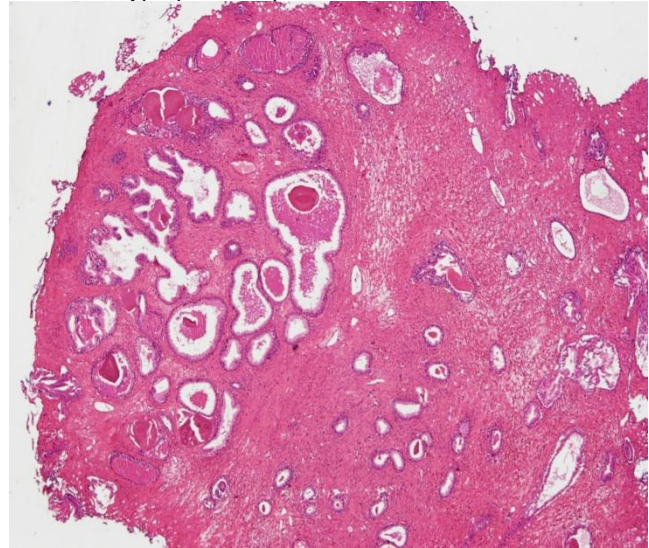
## CONCLUSIONS

Following conclusions are drawn from present study:-

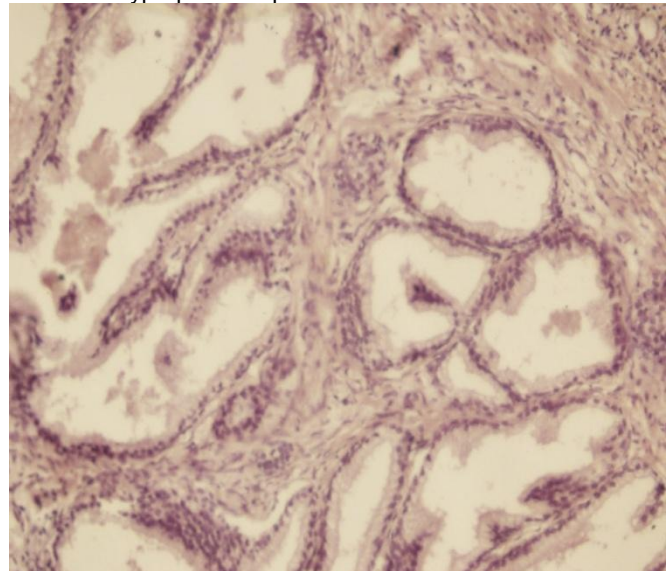
- The patients with prostatic hyperplasia usually presented in 6<sup>th</sup> decade whereas patients with cancer mostly presented in 7<sup>th</sup> decade. It was concluded that patients present late with more advanced tumors in our region.
- Mostly the diagnosis of prostate cancer is dependent on H&E criteria. But there are situations in which H&E features fall short for those required for an outright diagnosis of malignancy. AMACR is a useful immunohistochemical marker for accurate and prompt detection of prostate cancer in full range

of prostate biopsies encountered in surgical pathology. Our observations and studies to date on AMACR clearly emphasize the useful role of this novel marker to support a diagnosis of malignancy in prostate specimens. It was therefore concluded that AMACR increases diagnostic yield. So it can be used for diagnosing the challenging cases of prostate cancer at early stages. However we recommend studies on large-scale and continuous monitoring of newly diagnosed cases. As incidence of prostate cancer is increasing in our region, every effort should be made for appropriate measures towards possible prevention by avoiding risk factors.

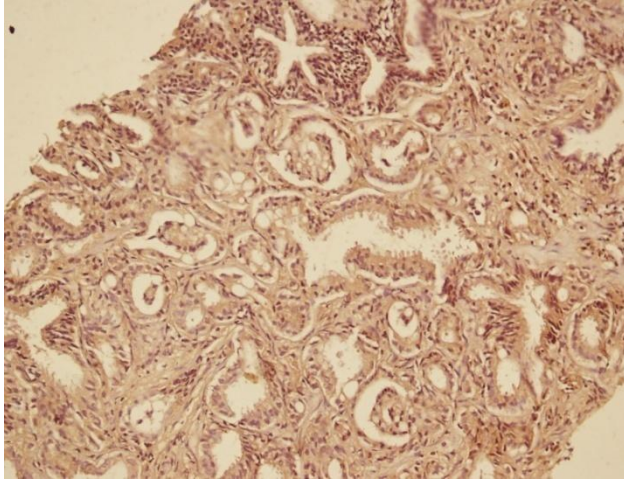
Glandular hyperplasia of prostate - H&E-400X



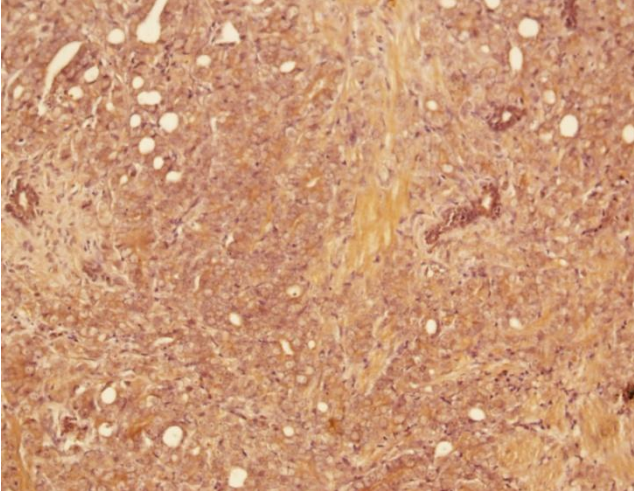
Glandular hyperplasia of prostate AMACR-400X



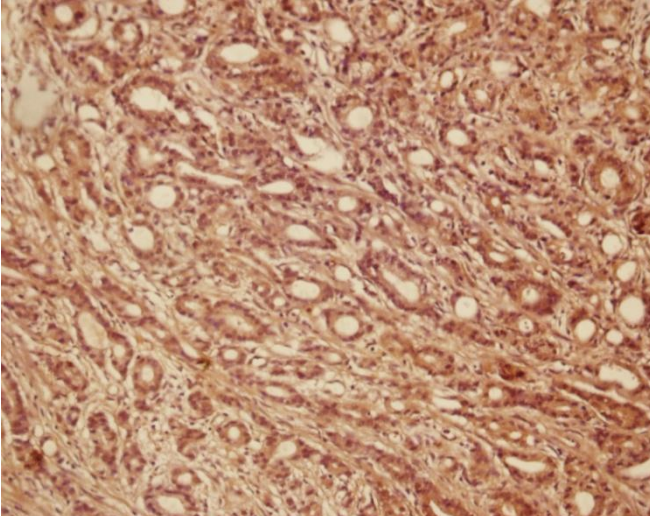
Prostate Carcinoma 6(3+3) AMACR-400X



Prostate Carcinoma 9(4+5) AMACR-400X



Prostate Carcinoma 7(3+4) AMACR-400X



## REFERENCES

1. Ferlay J, Bray F, Pisani P. Globocan 2002: Cancer incidence, mortality and prevalence worldwide. Version 2.0. Lyon, France; IARC Press; 2004. IARC Cancer Base No.5.
2. Jemal A, Siegel R, Ward E, Murray T, Xu J, Smigal C, et al. Cancer statistics. CA: a Cancer J Clin. 2006; 56:106–130.
3. Shin HR, Carlos MC, Varghese C (2012). Cancer control in the Asia Pacific region: current status and concerns. Jpn J ClinOncol. 2012; 42:867-81.
4. Thomson AH, Kulkarni S, Bahl A. Primary cryotherapy with salvage external beam radiotherapy for locally recurrent prostate cancer. ClinOncol. 2008; 20:385.
5. Donovan MJ, Cordon-Cardo C. Predicting high-risk disease using tissue biomarkers. Curr Opin Urol. 2013; 23: 245–250.
6. Loeb S, Catalona WJ. Prostate specific antigen in clinical practice. Cancer Lett. 2007; 249:30-39.
7. Humphrey PA. Diagnosis of adenocarcinoma in prostate needle biopsy tissue. J ClinPathol. 2007; 60:35-42.
8. Ng V W L, Koh M, Tan S Y. Is triple immunostaining with 34 $\beta$ E12, p63 and racemase in prostate cancer advantageous? Am J ClinPathol. 2007;127:248-253.
9. Kumaresan K, Kakkar N, Verma A, Mandal AK, Singh SK, Joshi K. Diagnostic utility of  $\alpha$ -methylacyl CoA racemase and HMWCK in morphologically difficult prostate cancer. Diagn. Pathol. 2010; 5:83.
10. Halushka M, Kashefi H. Negative 34 $\beta$ E12 staining in a small focus of atypical glands on prostate needle biopsy: a follow-up study of 332 cases. Hum. Pathol. 2008; 35:43-46.
11. Carter HB, Isaacs WB. Improved Biomarkers for Prostate Cancer: A definite need. JNCI Journal of the national cancer institute 2004; 96:813-815.
12. Kumar Sinha C, Shah RB, Laxman B, Tomlins S A, et al. Elevated alpha-methylacyl-CoA racemase enzymatic activity in prostate cancer. Am J Pathol. 2004;164:787-793.
13. Jiang Z, Woda BA, Rock KL. P504S: a new molecular marker for the detection of prostate carcinoma. Am. J. Surg.Pathol. 2001; 25:1397-1404.
14. Rubin MA, Zhou M, Dhanasekaran SM. Alpha methylacyl coenzyme A racemase as a tissue biomarker for prostate cancer. JAMA. 2002;287:1662-1670.
15. Luo J, Zha S, Gage WR. Alpha-methylacyl-CoA racemase: a new molecular marker for prostate cancer. CancerRes. 2002; 62: 2220-2226.
16. Beach R, Gown AM, De Peralta-Venturina MN. P504S immunohistochemical detection in 405 prostatic specimens including 376 18-gauge needle biopsies. Am J SurgPathol.2002;26:1588-1596.
17. Miller K. Immunocytochemical Techniques. In: Bancroft JD & Gamble M. Theory and practice of histological techniques, 5<sup>th</sup>ed, Philadelphia, Churchill Livingstone. 2005; 421-458.
18. Mansoor I. Patterns of prostatic diseases in Saudi Arabia. IJP.2003; 2: 2.
19. Pervez A, Tareen S, Arif A, Farak A. Benign prostatic obstruction successfully treated by transurethral resection. Pak. J. Med. Res.2006; 45:4.
20. Sadjadi A, Nooraie M, Ghorbani A, Alimohammadian M, Zahedi MJ, Moghadam SD. The Incidence of Prostate Cancer in Iran: Results of a Population-Based Cancer Registry. Archives of Iranian Medicine. 2007; 10: 481-485.
21. Ahmed Z, Muzaffar S. Prostatic carcinoma with emphasis on Gleason's grading: an institutional base experience. JPMA. 2002; 52: 54.
22. Yang XJ, Tretiakova MS, Sengupta E. Florid basal cell hyperplasia of the prostate: a histological, ultrastructural, and immunohistochemical analysis. Hum. Pathol. 2003; 34:462.
23. Shah RB, Zhou M, LeBlanc M, Snyder M, Rubin MA. Comparison of the basal cell-specific markers, 34 $\beta$ E12

and p63, in the diagnosis of prostate cancer. Am JSurgPathol. 2002; 26:1161-1168.