

Analytical study of Choledocholithiasis & Cholelithiasis by using Ultrasound

ASRA YASIN¹, UMAMA SAEED², MAHAM MUNIR³

ABSTRACT

Background: This is analytical study of Cholelithiasis and choledocholithiasis by usage of ultrasonography. Cholelithiasis and choledocholithiasis is the presence of stones in gall bladder and in the common bile duct.

Aim: To analyze the role of ultrasound for assessment of cholelithiasis, Choledocholithiasis and acute cholecystitis.

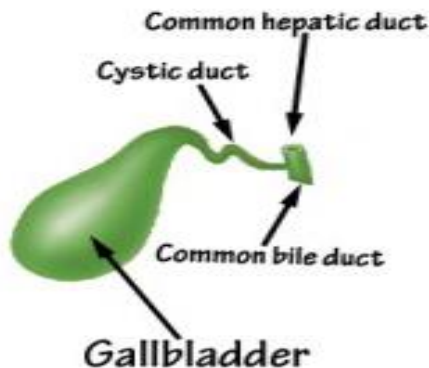
Methods: The study was conducted in Surgical Unit III in Nishtar hospital Multan from June 2016 to October 2016. Fifty patients were selected after taking consent from them and the higher authorities and all records were taken in term of age, sex of the patients, USG reports and all data was analyzed by using SPSS and epi info.

Results: In 50 patients, no gallbladder stones found in eight patients, in thirteen patients, stones were present in gallbladder neck and in seventeen patients, stones were in gallbladder lumen and in 12 patients stones were in gallbladder fundus.

Conclusion: Stones are more common in gall bladder lumen and CBD in old age women as compared to men and can be utmost diagnosed by using USG.

Keywords: Ultrasonography-USG, Common Bile Duct-CBD

INTRODUCTION



The gallbladder is a pear-shaped sac that can store 50 ml of bile. The underneath apparent of gallbladder is covered by peritoneum^{1,2}.

Transabdominal ultrasound and power color doppler scanning is the best methods for diagnosis cholelithiasis, choledocholithiasis and acute cholecystitis^{3,4}.

Approximately 90 to 95% of cases are due to stones obstacle of the gallbladder neck or cystic duct that can enhance intraluminal density and distention which ultimately result inflammation^{5,6}. Differential diagnosis for acute cholecystitis is as^{7,8,9}.

1. Choledocholithiasis
2. Pancreatitis

- 3: Peptic ulcer disease
- 4: Acute hepatitis
- 5: Liver abscess

This is analytical study of Cholelithiasis and choledocholithiasis by usage of ultrasonography. Cholelithiasis and choledocholithiasis is the presence of stones in gall bladder and in the common bile duct. The study was conducted to analyze the role of ultrasound for assessment of cholelithiasis, Choledocholithiasis and acute cholecystitis. The study was conducted in Surgical Unit III in Nishtar hospital Multan from June 2016 to October 2016. Fifty patients were selected after taking consent from them and the higher authorities and all records were taken in term of age, sex of the patients, USG reports and all data was analyzed by SPSS and epi info.

MATERIALS AND METHODS

The study was conducted in Surgical Unit III in Nishtar hospital Multan from June 2016 to October 2016. Fifty patients were selected after taking consent from them and the higher authorities and all records were taken in term of age, sex of the patients, USG reports and all data was analyzed by using SPSS and epi info.

RESULTS

The age of patients ranges from 68 years to 21 years .In this study 50 patients were scanned from which 20 were female & 30 were male. From 50

^{1,2}Senior Registrar Radiology Department CPEIC Multan
³Assistant Professor Radiology Department CPEIC Multan
Correspondence to Dr. Asra Yasin Email: mohdmpk@yahoo.com

patients, no gallbladder stones found in eight patients, in thirteen patients, stones were present in gallbladder neck and in 17 patients, stones were in gallbladder lumen & in 12 patients stones were in gallbladder fundus As in Table No-I. In thirty patients there were only single stone and in ten patients were contain double stones & two patients were contain more than two stones .

Table 1: Location of stones

| Location | n | % age |
|----------|----|-------|
| No stone | 8 | 16 |
| At neck | 13 | 26 |
| Gb lumen | 17 | 34 |
| Neck | 12 | 24 |

Image 1: Gallbladder shows a calculus

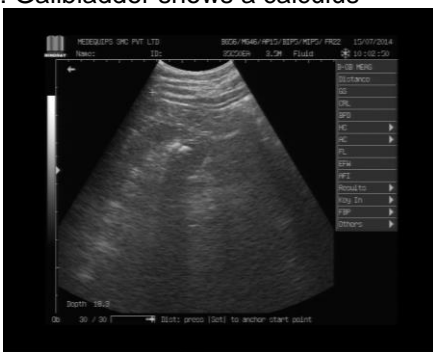

Image-2: Gallbladder shows two calculus

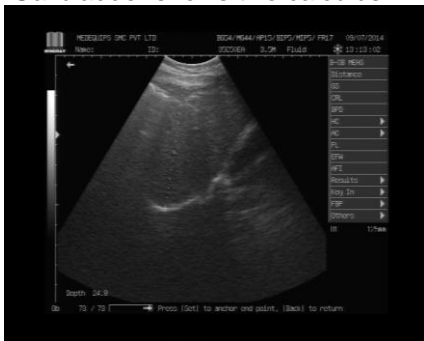
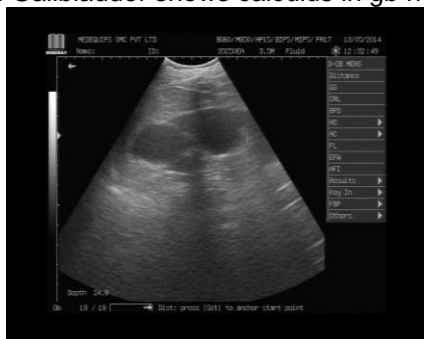

Image-3: Gallbladder shows calculus in gb neck



DISCUSSIONS

Gallstones can be asymptomatic or symptomatic. Patient's age ranges from 68 years to 21 years .In

this study 50 patients were scanned from which 20 were female & 30 were male. From 50 patients, no gallbladder stones found in eight patients, in thirteen patients, stones were present in gallbladder neck and in 17 patients, stones were in gallbladder lumen & in 12 patients stones were in gallbladder fundus As in Table No-I. In thirty patients there were only single stone and in ten patients were contain double stones & two patients were contain more than two stones. Ultrasonography reveals stones in gallbladder and common bile duct much more in old age women due to hormonal changes in old age and disrupt life styles and life practices including imbalance diet and nutrition.

CONCLUSION

Stones are more common in gall bladder lumen and CBD in old age women as compared to men and can be utmost diagnosed by using USG.

Recommendations: Ultrasound, best technique and procedure for identification of gallbladder stones. There is no other anatomic location in the body that is better studies with sonography than the biliary tree.

- Patients with gallstones may be asymptomatic which is an important point to remember when scanning a patients with abdominal pain.

REFERENCES

1. Shaffer EA. Gallstone disease: Epidemiology of gallbladder stone disease. *Best Pract Res ClinGastroenterol.* 2006;20 (6): 981-96. doi:10.1016/j.bpg.2006.05.004 -Pubmed citation
2. Hanbidge AE, Buckler PM, O'malley ME et-al. From the RSNA refresher courses: imaging evaluation for acute pain in the right upper quadrant. *Radiographics.* 24 (4): 1117-35. doi:10.1148/rg.244035149 - Pubmed citation
3. Bortoff GA, Chen MY, Ott DJ et-al. Gallbladder stones: imaging and intervention. *Radiographics.* 2000;20 (3): 751-66. *Radiographics (full text) - Pubmed citation*
4. Chuang S-C, Hsi E, Lee K-T. Genetics of gallstone disease. *Adv. Clin. Chem.* [Internet]. 2013 Jan [cited 2013 Nov 12];60:143–85. Pubmed citation
5. Gilani SNS, Bass G, Leader F, Walsh TN. Collins' sign: validation of a clinical sign in cholelithiasis. *Ir. J. Med. Sci.* [Internet]. 2009 Dec [cited 2013 Nov 12];178(4):397–400. Pubmed citation
6. Kothari SN, Obinwanne KM, Baker MT, Mathiason MA, Kallies KJ. A prospective, blinded comparison of laparoscopic ultrasound with transabdominal ultrasound for the detection of gallbladder pathology in morbidly obese patients. *J. Am. Coll. Surg.* [Internet]. 2013 Jun [cited 2013 Nov 12];216(6):1057–62. Pubmed citation
7. Altun E, Semelka RC, Elias J et-al. Acutecholecystitis: MR findings and differentiation from chronic cholecystitis. *Radiology.* 2007;244 (1): 174-83.doi:10.1148/radiol.2441060920 - Pubmed citation
8. Cooperberg PL, Gibney RG. Imaging of the gallbladder, 1987. *Radiology.* 1987;163 (3): 605-13. *Radiology (abstract) - Pubmed citation*
9. O'connor OJ, Maher MM. Imaging of cholecystitis. *AJR Am J Roentgenol.* 2011;196 (4): W367-74. doi:10.2214/ AJR.10.4340-Pubmed citation

