

CASE REPORT

Double Aortic Arch: An Uncommon Cause of Stridor in an Infant

MOHAMMAD ASJAD KHAN, ABDUL WAHEED, IKRAM MASOOD

Saud Al Babtain Cardiac Center, P.O Box 11850 Dammam, Saudi Arabia

Correspondence to Dr. Mohammad Asjad Khan Email: kasjad@hotmail.com

SUMMARY

A male infant six months of age presented with stridor. Echo, MRI, cardiac catheterization confirmed the diagnosis of double aortic arch. The child underwent successful surgery. The case is reported as an uncommon cardiac anomaly and an uncommon cause of stridor in an infant.

Keywords: Stridor, Double Aortic Arch, Subclavian Artery, Thoracotomy, Ligamentum Arteriosum, Aortopexy, Stenosis, Trachea

ETIOLOGY

The classical double aortic arch anatomy develops when involution of the distal right fourth arch does not take place. The fourth right and left arches both persist and form the left sided descending thoracic aorta. The right and left arches encircle the trachea and oesophagus. The double aortic arch then forms a ring around the trachea and oesophagus. The defect is rarely associated with other intra cardiac defect. Factors responsible for aberrant persistence of double arch segment have not been clearly identified. Band 22q11 deletion was found in 3 of 22 patients (14%) in double aortic arch¹.

Anatomy

In a double aortic arch both arches may be patent or an atretic segment may be present at one of the segments located in either arch. When both arches are patent one may be larger than the other or both may be similar in size.

In 75% of patient with double aortic arch the right arch is larger than the left. Associated cardiac anomaly, one fifth have other congenital cardiac defect; tetralogy of fallot, ventricular septal defect, coarctation of aorta², truncus arteriosus, patent ductus arteriosus, transposition of the great arteries³.

Fig. 1 MRI larger Rt. Aortic and smaller Lt. Aortic Arch

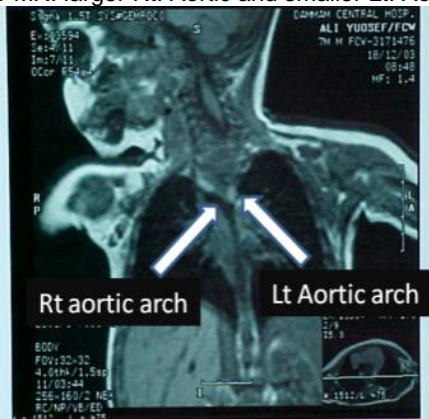


Fig. 2 MRI Double Aortic Arch forming a complete circle

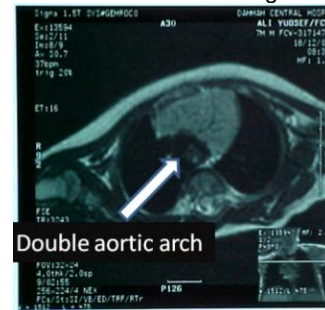


Fig. 3: Angiogram showing stenosis in Lt. Arch distal to origin of Lt. Subclavian Artery

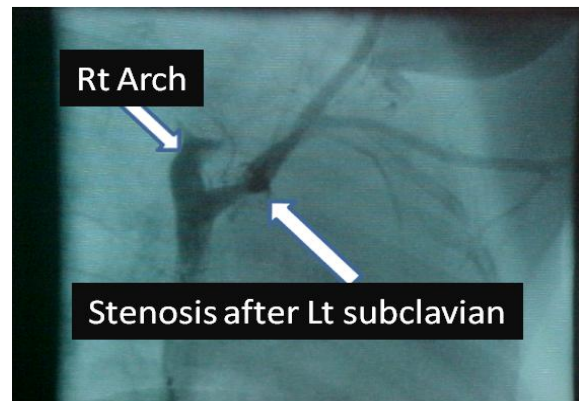


Fig. 4: Angiogram showing small Lt. Arch in lateral view

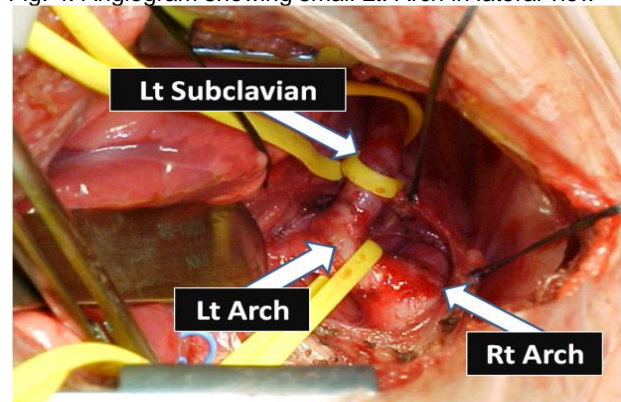


Fig. 5: Operation picture showing Lt. Subclavian Artery, Lt Aortic Arch and Rt. Aortic Arch

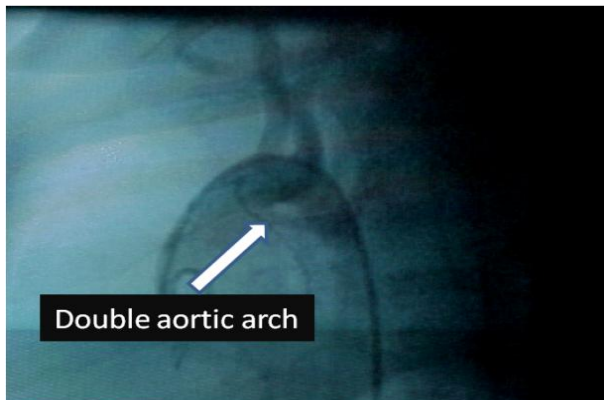
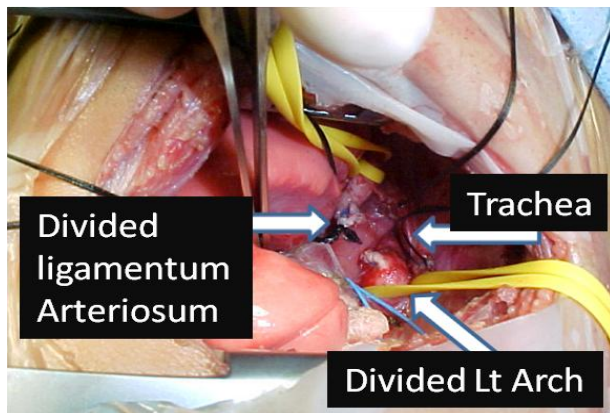


Fig. 6: Operative showing the division of Ligamentum Arteriosum and the Lt Aortic Arch



CASE REPORT

6 month old boy referred to us with stridor. Echo cardiography suggested double aortic arch. MRI Fig. 1 & 2 and cardiac catheterization Fig. 3& 4 confirmed the diagnosis. In cardiac catheterization it can be seen that there is stenosis distal to the origin of the left subclavian artery.

Treatment: Under general anaesthesia, central line and bilateral radial arterial line were placed. Left lateral thoracotomy was done the Lt Aortic Arch, Rt. Aortic Arch and Lt. Subclavian Artery were identified Fig. 5; the ligamentum arteriosum was divided after being ligated. The left arch was divided distal to the origin of the left subclavian artery and after minimal mobilization the trachea could be seen Fig. 6. Chest drain was placed. In ICU post extubation the stridor disappeared completely and the child was discharged home four days later.

The risk of the procedure is extremely low⁴. Outcome is usually good. However in some patients obstruction of the airway persists. Symptoms may improve after aortopexy is performed⁵. Robotic assistance division has been performed⁶, as well as video assisted thoracoscopic vascular ring division⁷.

DISCUSSION

The treatment of double aortic arch is undertaken by division of the non dominant arch after it is established as the cause of compression of the trachea. In our case the cardiac catheterization had shown stenosis distal to the origin of the left subclavian artery therefore the non dominant left arch was divided distal to the origin of the left subclavian to ensure that there is no compromise in blood flow. Thus the site of division is decided according to the anatomical variation as dominance of arch, stenosis or atretic segment ensuring the blood flow to the head and neck vessels remains normal.

Conflict of Interest: The authors have no conflict of interest to declare.

REFERENCES

1. McElhinney DB, Clark BJ 3rd, Weinberg PM, Kenton ML, McDonald McGinn D, Driscoll DA, et al. Association of chromosome 22q11 deletion with isolated anomalies of aortic arch laterality and branching *J Am Coll Cardiol*, Jun 15, 2001;37 (B);2114-9. [Medline]
2. Romanos A N, Bruin C L, Brom A D 1957 Rare Anomaly of the Aortic Arch combined with coarctation of Aorta. *Diseases of the chest* 31:540-547
3. Zdebska E, Smolska I, Markow M, Mi Ezynski W 1977. Early diagnosis and surgical treatment of children with congenital vascular rings and accompanying heart lesions. *J Pediatr. Surg* 12:121-124
4. Ruzmetov M, Vijay P, Rodefeld MD, Turrentine MVV, Brown JVV. Follow-up of surgical correction of aortic arch anomalies causing tracheoesophageal compression, a 38-year single institution experience. *J Pediatr. Surg.* Jul 2009, 44(7) 1328-32. [Medline]
5. Fraga JC, Calkoen FE, Gabra HO, McLaren CA, Roebuck DJ, Elliot MJ, Aortepexy for persistent tracheal obstruction after double aortic arch repair. *J Pediatr. Surg.* Jul 2009;1454-7. [Medline]
6. Mihaljevic T, Cannon JVV, del Nido PJ, Robotically assisted division of a vascular ring in children. *J Thorac. Cardiovasc. Surg.* May 2003;125(5):1163-4. [Medline]
7. Burke RP, Rosenfeld HM, Wemovsky G, Jonas RA Video-assisted thoracoscopic vascular ring division in infants and children, *J Am Coll Cardiol*, Mar 15, 1995;25(4);943-7. [Medline].