

# Comparison of Diagnostic Efficacy of Double Contrast Barium Meal Examination with Endoscopy in Diagnosis of Peptic Ulcer

ASIM RAHIM<sup>1</sup>, FARAH KALSOOM<sup>2</sup>, M. KALEEM QAISARANI<sup>3</sup>, M. MUSTAFA ALI SIDDIQUI<sup>4</sup>, M. MOHSIN KHAN<sup>5</sup>

## ABSTRACT

**Aim:** To see whether the double contrast barium meal examination can be used as diagnostic or screening tool or for both purposes.

**Methods:** This comparative study was carried out in the Radiology Department and Endoscopy unit of CMH, Multan from January 2010 to December 2012. A total of 150 patients with strong history of acid peptic disease and referred to radiology department for DCMB examination from surgery or medicine outpatient or inpatient department were included in the study.

**Results:** The potential accuracy of double contrast barium meal is 86% of endoscopy. The DCMB is considered to be the best screening and diagnostic tool while endoscopy should be reserved for those cases who have equivocal results on DCMB or who need therapeutic intervention.

**Conclusion:** It is concluded from the study that endoscopy is more sensitive and specific than the DCMB in diagnosing lesions of the upper GIT.

**Keywords:** Double contrast barium meal, Endoscopy, gastric ulcer.

## INTRODUCTION

With the advent of modern fiber optic instrument, endoscopic examination of the esophagus, stomach and duodenum can be performed with ease and little discomfort or any risk to the patient. The increasing availability and application of fiber optic endoscopy has provided us the opportunity to evaluate the diagnostic accuracy of barium studies of the stomach and duodenum<sup>1</sup>. The double contrast barium meal (DCBM) may be a new dependable technique for usual radiological diagnosis of dyspepsia<sup>2</sup>.

The best radiologic results with double contrast studies show radiology to have sensitivity of up to 95% of lesions found at endoscopy. Disagreement continues as to whether single contrast; double contrast or biphasic radiologic examinations are superior. The biphasic study, combining the best features of all the different techniques, out to provide the optimal results<sup>3</sup>. DCMB and endoscopy are both used in the investigation of patient presenting for the first time with dyspepsia. The choice of procedure may be determined by sensitivity, cost and safety<sup>4</sup>.

In spite of the growing accessibility of endoscopy and widespread use of H2 receptor antagonists, barium meal examination remains popular, accounting for over 17% of all general practitioner request for X-ray examinations in the

hospitals and second only in frequency to requests for chest X-ray examinations<sup>5</sup>. The barium meal is the preliminary examination in many hospitals for patients presenting with upper GI disorders. When DCMB technique is used, the diagnostic accuracy of radiology of the upper GIT is only marginally inferior to endoscopy while possessing the advantage of speed, safety, patient comfort and the avoidance of sedation drugs<sup>6</sup>. Endoscopy is superior in the duodenum in the rare lesion of anterior stomach wall and after partial gastrectomy or gastroenterostomy<sup>7</sup>.

## MATERIAL AND METHODS

This comparative study was carried out in the Radiology Department and Endoscopy unit of CMH, Multan from January 2010 to December 2012. A total of 150 patients with strong history of acid peptic disease and referred to radiology department for DCMB examination from surgery or medicine outpatient or inpatient department were included in the study.

## RESULTS

Comparative results of gastroscopy and DCMB for diagnosis of peptic ulcer are shown in table-1. Other results are shown in following figures.

Table-1: Comparative results of gastroscopy/ DCMB

DCMB	Endoscopy		Total
	Positive	Negative	
Positive	21	09	30
Negative	12	108	120

<sup>1</sup>Assistant Prof. MMDC, Multan,

<sup>2</sup>Sr. Registrar Radiology, NMC, Multan,

<sup>3</sup>Asstt. Prof. Radiology, MIKD, Multan,

<sup>4</sup>Assistant professor radiology, CPEIC, Multan,

<sup>5</sup>Professor Comm. Medicine, Amna Inyat Medical College, Lahore.

Correspondence to Dr. Asim Rahim  
E.mail:arahim2002@yahoo.com Cell: 032163996440

Fig. 1: Ulcer crater surrounded by radiolucent halo




Fig. 2: DCMB shows contracted small stomach with distorted mucosal lining.

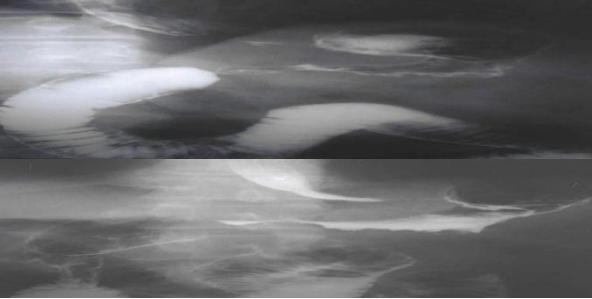


Fig.3: Gas filled view of DCMB of an old patient demonstrating a constricting and highly irregular mucosa



Fig. 4: DCMB of a young patients shows the cicatrized duodenal cap

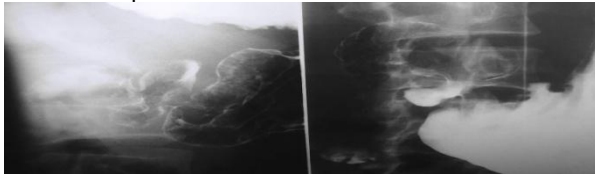


Fig. 5: On DCMB of a young patient there is barium collection in the ulcer crater

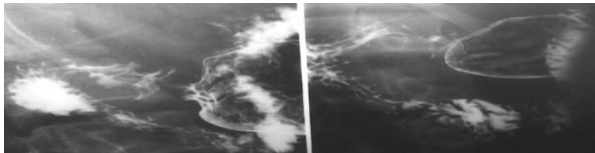
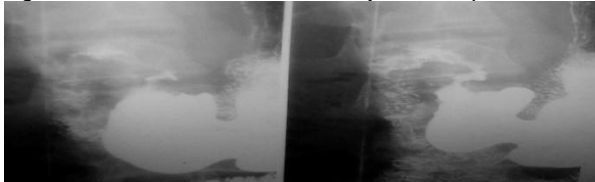


Fig. 6: DCMB examination of a 36 years old patients



## DISCUSSION

A recent investigation of the upper gastrointestinal series and its effects on clinical examination reviewed the impact of the radiologic study on 199 patients, who were followed for one year or more after their examination<sup>8</sup>. The upper gastrointestinal series achieved a 70% overall sensitivity, which improved to 87% if mild esophagitis, gastritis, duodenitis and postoperative cases were excluded. Thus it appears that there is nothing to be gained by routine employment of endoscopy as the initial examination of the upper gastrointestinal tract, as was recently suggested particularly if the significantly greater dangers and costs of the endoscopic study are considered<sup>3</sup>.

Cotton<sup>9</sup> stated that 73 ulcers diagnosed radiologically, four were not seen on endoscopy, one of which was known to be missed. Fraser and Earnshaw<sup>10</sup> found that 13% of gastric ulcers confidently diagnosed radiologically are undetected at endoscopy. The previous percentage of gastric ulcers detected on barium meal was 73-95%<sup>11,12</sup>.

The potential accuracy of the DCBM was calculated to 96% of that accorded to fiber endoscopy. Endoscopy has missed one lesser curve gastric ulcer just beyond the angulus where it was hidden by edema, one greater curvature ulcer situated immediately beyond a stricture and two gastric ulcer areas. These findings underline the conclusions of the authors<sup>13,14</sup>, who have stressed that gastrobular endoscopy and the DCBM are complementary and that both techniques may be required to achieve maximum diagnostic accuracy<sup>15</sup>.

It is studied that 441 successive patients for endoscopy after a negative double contrast barium meal were studied to determine the reliability of good quality radiology in excluding significant upper gastrointestinal pathology<sup>6</sup>. Endoscopic abnormalities were detected in 23 (5.2%) patients, nine of which were reporting errors.

Martin and colleagues found that 36 lesions initially seen radiologically were detected without error by two endoscopists when both had knowledge of the radiologic findings<sup>3</sup>. A considerably greater error rate was suggested by the interobserver variation study, in which the findings of three endoscopists of varying experience were compared for accuracy in the diagnosis of gastric ulcer<sup>16</sup>. Forty five ulcers were seen by one or more of the endoscopists, individual endoscopic sensitivity ranged from 62-77%<sup>16,17</sup>.

## CONCLUSION

It is concluded from the study that endoscopy is more sensitive and specific than the DCMB in diagnosing lesions of the upper GIT.

## REFERENCES

1. Role of barium meal examination in diagnosis of peptic ulcer. *J Ayub Med Coll Abbottabad* 2008; 20(4): 59-61.
2. Koivisto TT, Voutilainen ME, Färkkilä MA. Symptoms, endoscopic findings and histology predicting symptomatic benefit of helicobacter pylori eradication. *Scand J Gastroenterol* 2008. 43(7): 810-6.
3. Sharma SK, Maharjan DK, Thapa PB Hospital based analytic study of peptic ulcer disease in patients with dyspeptic symptoms. *Kathmandu Univ Med J* 2009; 7(26): 135-8.
4. Nawaz M, JehNZAIB m, Khan K, Zari M. Role of barium meal examination in diagnosis of peptic ulcer. *bv J Ayub Med Coll Abbottabad*. 2008; 20(4): 59-61.
5. Levine MS. Peptic ulcers. In: Gore RM, Levine MS, Bralow L editors. *Textbook of Gastrointestinal Radiology*. 2<sup>nd</sup> ed. Philadelphia, Pa: WB Saunders;. 2000: 514-45.
6. Arfeen S. A negative double contrast barium meal – qualified reassurance. *Clin Radiol* 1987; 38: 49.50.
7. Miseiwicz JJ, Pounder RE, Vanables CW. *Diseases of the gut and pancreas*. Cambridge: Blackwell Scientific Publication. 1994; pp 188-9.
8. Mybitz HA, Gelfand DW, Ott DJ. Upper gastrointestinal series. *Gastriubtest Radiol* 1985; 10: 277.
9. Cotton PB. Fibroptic endoscopy and the barium meal results and implication. *Br Med J* 1973; 161: 165.
10. Fraser GM, Earnshaw PM. The double contrast barium meal. *Clin Radiol* 1983; 34: 121.
11. Perna G, Houda T, Morrissey JF. Gastrocamera photography. *Arch Intern Med* 1965; 116: 434-41.
12. Gabreiellsson N. Gastric ulceration by gastrophotography. *Acta Radiol* 1971; 11: 59-68.
13. Remmer M, Bottger E, Adolphs HP, Manegold BC. Vergleichendeuntersuchunguber die diagnoseköglichkeiten des duodenums. *Fortschritte auf dem Gebiete der Rotentgenstran strahlenund der Nuklearmedizin* 1974; 121: 744-9.
14. Cumberland DC. Fiber optic endoscopy and radiology in the investigation of upper GIT. *Clin Radiol* 1975; 26: 233-6.
15. Herlinger H. An evaluation of the double contrast barium meal against endoscopy. *Clin Radiol* 1977; 28: 307-14.
16. Gjorup T, Agner E, Jensen LB. The endoscopic diagnosis of gastric ulcer. *Scand J Gastroenterol* 1995; 20: 554.
17. Hadenand N, Krus A, Madsen EH, Mathiasen MS. X-ray examination of endoscopy? *Gastrointest RAdiol* 1977; 1: 331-4.
18. Dooley CP. Double contrast barium meal and upper gastrointestinal endoscopy. *Ann Int Med* 1984; 101: 538-45.