

# The Anomalous Origin and Course of Coronaries in Tetralogy of Fallot (TOF)

SYED NAJAM HYDER, ASIM KHAN, ALI HASAN\*, NOORMAH MEHMOOD\*

## ABSTRACT

**Background:** The cyanotic heart disease Tetralogy (TOF) is one of the common congenital heart disease in children. The catheterization of such patients still considered as important diagnostic step before surgical correction. The prevalence of abnormal coronaries in Tetralogy (TOF) has been reported up to 9% in different studies. Coronary abnormalities are usually difficult to delineate intraoperatively because of thick epicardial fat layer and adhesions particularly after BT shunt.

**Aim:** To find out coronary abnormalities in Tetralogy of Fallot (TOF) children seen in our cardiac unit.

**Place and Duration of Study:** The study was conducted in the Children hospital & Institute of Child Health, Lahore, Pakistan from January 2006 to December 2014.

**Methods:** A Retrospective descriptive study was done .Records of all Patients with Tetralogy of Fallot from 9 months to 16 years whose cardiac catheterization was done before going to surgical repair in our unit were selected in this study. Two Non-selective aortic root angiogram were done i.e., standard 45 left anterior oblique (LAO) and 20 cranial and 30 right anterior oblique (RAO) views were taken to look for coronaries course. Data was analyzed in SSPS-19.

**Results:** Total 662 patients with Tetralogy underwent cardiac catheterization were included in the study. 65.4% were male while 34.6% were female. The mean age was 69±43.14 months. 94.4% of patients with Tetralogy had a normal coronary anatomy while 5.6% of patients with Tetralogy had abnormal coronary course. Out of these patients with abnormal coronary, the most common was detected single origin of coronary artery that is 2.9% of cases. Out of which 12 patients had common origin from left sided sinus i.e., 1.8% and 7 patients had common origin from right sided sinus i.e., 1.1%. 2.6% of patients with abnormal coronary had coanal branch crossing right ventricular outflow track (RVOT) anteriorly and 0.2% of patients with abnormal coronaries had coanal branch crossing RVOT posteriorly.

**Conclusion:** Coronary artery anomalies and its course in Tetralogy patients were detected upto 5.6% of the cases. Single origin coronary artery abnormality was found to be the most common abnormality in this study.

**Keywords:** *Coronary abnormality. Catheterization. Tetralogy of Fallot. Single origin coronary artery.*

---

## INTRODUCTION

Tetralogy (TOF) is one of the most common cyanotic congenital heart diseases in childhood<sup>1</sup>. In angiographic, surgical, and autopsy series, coronary artery anomalies (CAA) have been reported in 2% to 14% of patients with TOF<sup>2</sup>. Anomalies of coronary arteries involving the anterior wall of the right ventricle are highly significant. These anomalies, if not detected preoperatively, can lead to major problems at operation<sup>3,4</sup>. In some cases, the anomalous coronary artery may be undetectable intraoperatively, especially when it is obscured by the overlying myocardium<sup>5,6</sup>, or epicardial fat<sup>7,8</sup>, or by pericardial adhesions<sup>9,10</sup> due to previous palliative surgery. Pre-operative recognition of such arteries is

therefore crucial in deciding the time and type of procedure to be performed<sup>11,12</sup>. The study was conducted to investigate the frequency of abnormalities of coronary arteries by an angiographic methods in Tetralogy of fallot patients, and to confirm the surgical importance of coronary abnormality. An unrecognized inadvertent division of such a vessel during incision for corrective surgery can lead to myocardial infarction or death<sup>13</sup>.

In adults CT coronary angiography and MRI has an established role in diagnosis of coronary artery anomalies. As young children have higher heart rates and are unable to hold the breath during examination, good quality CT is difficult to obtain. MRI has also a limited role for assessment of coronaries in children due to poor temporal resolution. It may require general anaesthesia as well<sup>14,15</sup>. There is also an increasing evidence of coronary assessment by echocardiography but this modality has a low sensitivity in various studies.<sup>13,16</sup> Therefore

---

*Department of Paediatric Cardiology & Cardiac Surgery,  
The Children's Hospital & ICH, Lahore.*

*\*Aga Khan University Karachi*

*Correspondence to Dr. Syed Najam Hyder Email:  
najamhyder@gmail.com cell: 0333-4262250*

angiography in Tetralogy is important to evaluate the abnormality of coronary arteries.<sup>17</sup>

**METHODS**

The angiographic records taken from Jan 2006 to December 2014 of patients with Tetralogy of Fallot . Only those patients were included who had one cardiac lesion and had no other associated complications or anomalies.

Patients with associated other lesions and those patient who were operated without angiography in emergency were excluded from the study group. In order to find out the abnormality of coronaries we analyzed retrospectively the cineangiocardiograms of all patients of Tetralogy of Fallot. All abnormalities of coronary arteries were enrolled in the study. Also, an enlarged conal branch of the right coronary artery (RCA) was considered as an anomaly when it was remarkably developed, enlarged, and ran towards the RVOT. Angiocardiograms performed in Cardiology Department, The Children Hospital, Lahore using the Siemens Unicor Top System and interpreted by two experienced pediatric cardiologists simultaneously.

Data was collected from record files. Computer software SPSS version 19 was used for data entry and analysis. Frequency and percentages were calculated by univariate analysis.

**RESULTS**

Out of 662 patients only with Tetralogy who underwent cardiac catheterization were included. 65.4% were male and 34.6% were female (Fig. 1). The average age was found to be 69±43.14 months. 625 patients with Tetralogy 5.6% patients had abnormal coronary artery course (Fig. 2). Out of these patients with abnormal coronaries, the most common abnormality was found a single origin coronary artery in 2.9% of cases. Out of which 12 patients had common origin from left sided sinus (1.8%) and 7 patients had common origin from right sided sinus (1.1%) (Table 1). 2.6% patients with Tetralogy had coanal branch crossing through right ventricular outflow track (RVOT) anteriorly and in 0.2% patients with Tetralogy had coanal branch crossing through RVOT posteriorly.

Table 1: Coronaries abnormalities

Coronaries abnormalities	n	%age
Single origin coronaries	19	2.6
Left sided sinus origin	12	1.8
Right sided sinus origin	07	1.1
Coanal branch crossing RVOT anteriorly	17	2.6
Coanal branch crossing RVOT posteriorly	1	0.2

Fig.1: Gender Difference


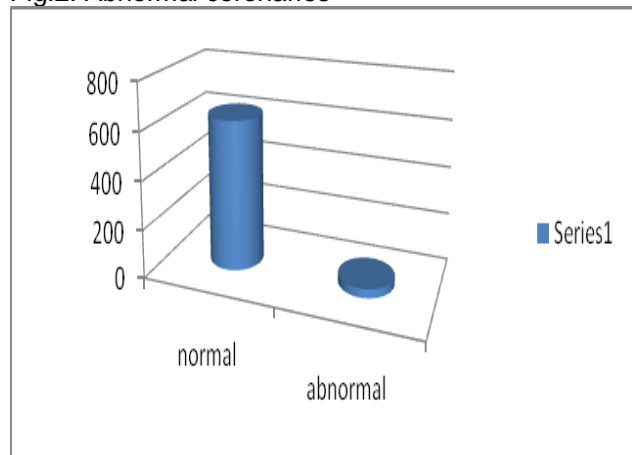


Fig.2: Abnormal coronaries



**DISCUSSION**

Although an anomalous coronary artery in itself may cause no recognized problems, it contributes significantly to morbidity and mortality rates during complete cardiac repair<sup>13</sup>. If coronary artery crosses the RVOT affects in surgical repair in patients with Tetralogy of Fallot<sup>14,17</sup>. Those patients in which coronary artery interfere with right ventriculotomy should be identified pre-operatively to avoid resection of vessels during resection of outflow tract obstruction. Usually sternotomy should not be required for palliation, or the coronary arteries may be preserved in previous surgery, or may present an intramural course<sup>15</sup>. The incidence of coronary artery anomalies (CAA) varies according to the methods used by investigators. In angiographic<sup>15,17</sup>, surgical<sup>10,11,13</sup>, and autopsy series, coronary artery abnormalities have been reported in 2% to 14% of patients with ToF<sup>16</sup>. In our study, we determined the coronary artery anomaly in 5.7% of patient with Tetralogy of Fallot. Some studies have reported that the incidence of the LAD or the accessory LAD arising from the RCA and single coronary artery is increased according to the degree of aortic

overriding, Since we included all abnormalities of the coronary arteries determined in the angiocardio-grams, the frequency of coronary artery anomaly was upto (5.7%) in our study. In angiographic studies, the incidence is varied by the use of ventriculography, aortography or selective coronary angiography, as well as the positions of the angiograms and their interpretations<sup>10,11</sup>. Our data was compatible with most previous studies, such as those by Fellows et al (4%), Dabizzi et al (4.9%) and Brizard et al (3.4%)<sup>14,15</sup>. The second common coronary artery anomaly in our study was single coronary ostium from one of the sinuses of Valsalva, as has been the case in most studies. In this situation, the anomalous vessels may cross over the proposed infundibular resection or travel around the RVOT and cause no surgical problems<sup>13</sup>. It was reported as 2.7% by Fellows et al<sup>12</sup>, 3.77% by Dabizzi et al<sup>11</sup> and 1.5% by Brizard et al<sup>16</sup>. Although a large conal branch of the RCA was not regarded in most previous studies to be an anomaly, when it is enlarged and courses over the right ventricular infundibulum it can present a serious hazard if unrecognized at the time of right ventriculotomy<sup>4,17</sup> and coronary artery fistulas. Coronary abnormalities found in 5-14% patients with Tetralogy<sup>5</sup>. Identification of coronary abnormalities is important to reduce the complications in the patients before planning primary repair.

## REFERENCES

- Toiyama K, Shiraishi I, Oka T et al. Assessment of coronary flow reserve with a Doppler guide wire in children with tetralogy of Fallot before and after surgical operation. *J Thorac Cardiovasc Surg*, 2004; 127: 1195–1197.
- Mawson JB. Congenital heart defects and coronary anatomy. *Tex Heart Inst J*, 2002; 29: 279–289.
- Asano M, Nomura N, Sasaki S, Mishima A. Surgical repair of tetralogy of Fallot with large conus artery. *Pediatr Cardiol*, 2003; 24: 601–603.
- Dabizzi RP, Caprioli G, Aiazzi L et al. Distribution and anomalies of coronary arteries in tetralogy of Fallot. *Circulation*, 1980; 61: 95–102.
- Kirklin JW, Ellis FJ Jr, McGoon DC, Dushane JW, Swan HJ. Surgical treatment for the tetralogy of Fallot by open intracardiac repair. *J Thorac Cardiovasc Surg*, 1959; 37: 33–37.
- Longenecker CG, Reemtsma K, Creech O. Anomalous coronary artery distribution associated with the tetralogy of Fallot: A hazard in open cardiac repair. *J Thorac Cardiovasc Surg*, 1961; 42: 258–262.
- Meng CCL, Eckner FAO, Lev M. Coronary artery distribution in tetralogy of Fallot. *Arch Surg*, 1965; 90: 363–366.
- White RI, Frech RS, Castaneda A, Amplatz K. The nature and significance of anomalous coronary arteries in tetralogy of Fallot. *Am J Roentgenol Rad Ther Nucl Med*, 1972; 114: 350–354.
- Friedman S, Ash R, Klein D, Johnson J. Anomalous single coronary artery complicating ventriculotomy in child with cyanotic congenital heart disease. *Am Heart J*, 1960; 59: 149–153.
- Berry BE, McGoon DC. Total correction for tetralogy of Fallot with anomalies coronary artery. *Surgery*, 1973; 74: 894–898.
- Meyer J, Chiariello L, Hallman GL, Cooley DA. Coronary artery anomalies in patients with tetralogy of Fallot. *J Thorac Cardiovasc Surg*, 1975; 69: 373–376.
- Li J, Soukias ND, Carvalho JS, Ho SY. Coronary arterial anatomy in tetralogy of Fallot: Morphological and clinical correlations. *Heart*, 1998; 80: 174–183.
- Humes RA, Driscoll DJ, Danielson GK, Puga FJ. Tetralogy of fallot with anomalous origin of left anterior descending coronary artery: surgical options. *J Thorac Cardiovasc Surg* 1987; 94:784-7.
- Ou P, Celermajer DS, Calcagni G, Brunelle F, Bonnet D, Sidi D. Three-dimensional CT scanning: a new diagnostic modality in congenital heart disease. *Heart* 2007; 93:908-13.
- Taylor AM, Dymarkowski S, Hamaekers P, Razavi R, Mertens L, Bogaert J. MR coronary angiography and late-enhancement myocardial MR in children who underwent arterial switch surgery for transposition of great arteries. *Radiology* 2005; 234:542-7.
- Santoro G, Marino B, Di Carlo D, Formigari R, De Zorzi A, Mazzer E, et al. Echocardiographically guided repair of tetralogy of fallot. *Am J Cardiol* 1994; 73:808-11.
- Need LR, Powell AJ, del Nido P, Geva T. Coronary echocardiography in tetralogy of fallot: diagnostic accuracy, resource utilization and surgical implications over 13 years. *J Am Coll Cardiol* 2000; 36:1371-7.
- Fellows KE, Freed MD, Keane JF, Praagh R, Bernhard WF, Castaneda AC. Results of routine pre-operative coronary angiography in tetralogy of fallot. *Circulation* 1975; 51:561-6.